# Documentation Summaries

Issue 7

ASTRATECH DENTAL
Get inspired

# Astra Tech BioManagement Complex™

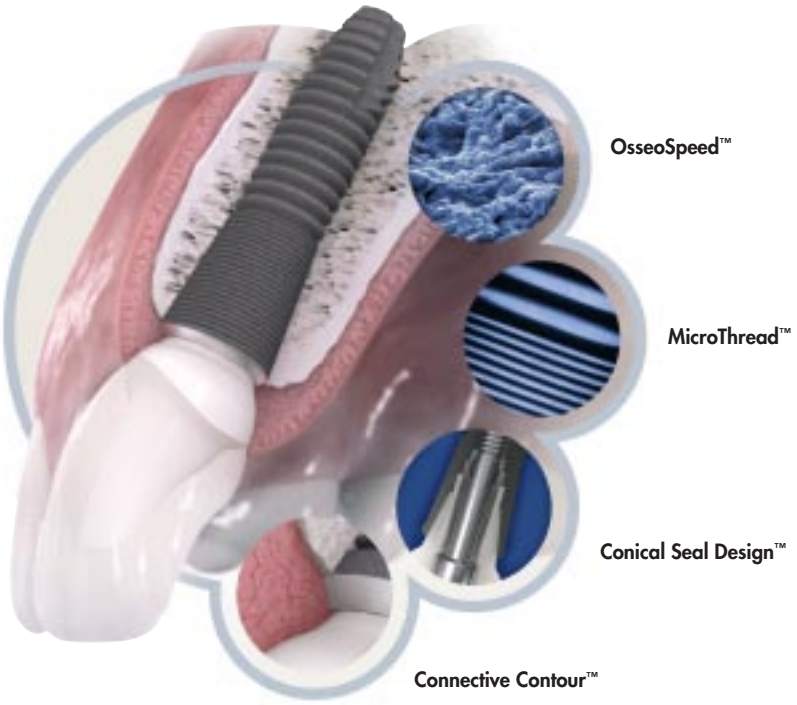


A successful implant system cannot be determined by one single feature alone. Just as in nature, there must be several interdependent features working together. The following combination of key features is unique to Astra Tech Implant System™:

- **OsseoSpeed™** — more bone more rapidly
- **MicroThread™** — biomechanical bone stimulation
- **Conical Seal Design™** — a strong and stable fit
- **Connective Contour™** — increased soft tissue contact zone and volume

**Publisher**

The Astra Tech "Documentation Summaries" is published and distributed by
Astra Tech AB, Box 14, SE-431 21 Mölndal, Sweden. Astra Tech is a company in the AstraZeneca Group.



**Reprints**

To order reprints of the articles summarised, please contact your local Astra Tech representative or the main office. For address please see page 91.

# Welcome

Are you looking for information about what implant design features are important for functional and esthetic results? Or do you want to read about the outstanding result on maintained marginal bone levels when using the Astra Tech Implant System™? This edition of Documentation Summaries will give you the answers.

The summaries are divided into the topics listed below. The sections on OsseoSpeed™, MicroThread™, Conical Seal Design™ and Connective Contour™ emphasize the key features of the Astra Tech BioManagement Complex™. The sections on Atlantis™, Cresco™ and Facilitate™ highlight freedom and open solutions from Astra Tech Dental.

We hope you will enjoy this edition of Documentation Summaries.

Content Astra Tech Documentation Summaries



For a more comprehensive view on the documentation and research on our products we kindly refer to the Scientific Reviews. The Scientific Reviews are available for download on the internet at www.astratechdental.com.

# OsseoSpeed™



OsseoSpeed™ is the implant with a chemically modified surface and a unique nanoscale topography. The OsseoSpeed implant has clearly improved results compared to earlier generations of implants. The following summaries of the pre-clinical and clinical scientific articles reveal the mechanisms behind the performance and clinical outcome.

## Pre-clinical



## Clinical



*To read more, please see 34, 40, 51, 54, 58, 79, 84*

# Bone healing at implants with a fluoride-modified surface: an experimental study in dogs

**Berglundh, T.**
**Abrahamsson, I.**
**Albouy, J.P.**
**Lindhe, J.**

**Clin Oral Impl Res**
2007;18, 147-152

**Purpose:** In the early loading or immediate loading protocol for dental implants it is recognized that a process occurs during the initial healing phase which transfers the retention of the implant from a mechanical to a biological phenomenon over a period of approximately 4 weeks. During this osseointegration phase a coagulum is seen to re-organize with granulation tissue which is subsequently replaced by a matrix that leads to new bone formation. The need to enhance or optimize conditions for osseointegration of the implant during this critical phase is important and has been shown to be improved by surface microtexturing. In addition some studies have indicated that there may be some additional benefits derived from biochemical modifications, in particular the addition of fluoride ions on to the surface of the implant. This study set out to evaluate the effects of fluoride on the early stages of osseointegration by histological examination.

**Materials and Methods:** Six mongrel dogs had all their mandibular premolars and first mandibular molars extracted. Three months later one side of the mandible was exposed and 6 implants were placed. Two geometrically identical implants were used, and both were equipped with MicroThread™ on the implant neck. The control implants had a TiOblast™ surface (TiOblast™, Astra Tech), (TB) and the test implants had a fluoride modified surface (OsseoSpeed™, Astra Tech) (OS). The surface roughness (Sa) was moderate in both cases and were for TB 1–1.2 µm and for OS 1.4-1.5 µm. Four weeks after the first implants were randomly placed the procedure was repeated on the contralateral side of the mandible. After a further 2 weeks of healing the animals were sacrificed, and each implant was removed *en bloc* and prepared for histological analysis of either fractured decalcified 3 µm sections stained with toluidine blue or 20 µm ground sections also stained with toluidine blue. The degree of bone-to-implant contact (% BIC) was assessed within the micro- and macro-threaded portion of all the implants. The tissue filling the void between the cut bone wall and the macro-threads of the implant immediately following implant installation was also evaluated to study early bone formation. Differences between the implant types were analyzed using student's t-test, at the 95% confidence level.

**Results:** Healing was uneventful and no implants were lost. After 2 and 6 weeks the % BIC at the MicroThread portion of both the TB and OS implants were similar. In the macro-threaded portion at 2 weeks the % BIC was 57% for the OS implants and 43% for the TB implants, ($p < 0.05$). At 6 weeks respective values were 61% and 59%. The % BIC in the wound chamber showed a significant difference at 2 weeks with 72% for OS implants compared to 60% for the TB implants, ($p < 0.05$). At 6 weeks respective values were 61% and 67%.

With respect to the tissue composition, after 2 weeks the wound chamber had 25–30% mineralized bone, which mainly consisted of woven bone (approx 20%). The amount of mineralized bone increased to approximately 50% at 6 weeks with a significant decrease in the constituent proportion of woven bone which had been replaced by lamellar bone. Tissue composition and proportion was similar at both TB and OS implants.

**Discussion and Conclusion:** Previous studies have demonstrated the influence of surface roughness to enhance the rate of early bone formation and osseointegration. Typically these studies have compared roughened implants to machined implants where differences in the Sa values are considerable. In the current study a microtextured implant was used as the control and as such had a similar Sa value to that of the test implant which was modified only by the incorporation of fluoride ions. The finding that there was significantly more new bone formed within the wound chamber and along the macro-threaded portion of the OS implant surface at 2 weeks is noteworthy since it suggests that the fluoride modified surface enhances and promotes osseointegration in the early phase of healing following implant installation and that in this particular test it was not dependent on surface roughness. These findings are in agreement with previously published data from Ellingsen et al (JOMI, 2004) and Cooper et al (Biomaterials, 2006) which would imply that osteoblast differentiation and new bone formation is enhanced by the addition of fluoride.

# Pre-treatment of titanium implants with fluoride improves their retention in bone

**Ellingsen, J.E.**

**J Mater Sci: Mater Med**
1995;6, 749-753

**Purpose:** The purpose of this study was to investigate the reaction between fluoride ions on a titanium surface and bone to determine if a chemical bond exists.

**Materials and Methods:** Test implants 5 mm long and tapered from a diameter of 3 mm to 2 mm at the apical end were fabricated from commercial pure titanium. A total of 64 implants were placed into the bilateral ulnas of 16 chinchilla rabbits. Two groups of implants were created, a control group which were left as machined and a test group which received one of three types of fluoride acid wash pre-treatment at a pH of 3.0 or 3.5 and a concentration of 0.5% or 4% NaF to create a thin fluoride layer on the titanium surface. In the first group, one test and one control implant were placed unilaterally into osteotomies that allowed a frictionless insertion under a load of 360 g. Four weeks later a second test and control implant were inserted into the contralateral ulna. After a further four weeks of healing the animals were sacrificed and the two groups of implants subject to push out tests, using an Instrom tensile testing machine, with a load applied to the apical end of the tapered implants. Peak tensile loads were recorded. The surface of the implants was analyzed using scanning electron microscopy at 85 and 500 times magnification. The ulnas were then prepared for histological analysis of the implant sites using 15 µm sections stained with toluidine blue.

**Results:** The fluoride treated implants yielded higher push out values consistently at after both 4 and 8 weeks of healing, with a 3 to 4 fold increase in resistance. The higher concentration also gave rise to the greatest push out values. While there was some variation in the values for the test implants between 4 and 8 weeks, the control implants demonstrated a consistent lack of resistance regardless of time. The electron microscopy revealed an almost clean metallic surface for the control implants, compared to the presence of tissues on the test implants which indicated bone had fractured within the tissue itself leaving a layer adherent to the implant surface. This was supported by the histology which indicated the existence of an intimate bone-to-implant contact for test implants even in the cancellous compartment. Such an appearance was lacking for control implants.

**Discussion:** Calcium cations are divalent and are important in the establishment of a bone-to-implant contact when presented with a $TiO_2$ surface at physiologic pH. In addition the precipitation of calcium phosphate has been shown to be enhanced by the presence of $TiO_2$. The use of fluoride ions is thought to further optimize the process by allowing selective bonding of phosphate to the titanium surface by the release of fluoride forming a covalent bond with titanium. In addition fluoride has been shown to stimulate osteoprogenitor cells *in vitro* and may depress osteoclast activity through the formation of fluorapatite, which is less soluble. Fluoride has also been shown to increase alkaline phosphatase activity which is an indication of bone formation. All these responses will be dose dependant and in the current study concentration was seen to impact upon push out values. Certainly it can be concluded that the ability of fluoride to prevent the adhesion of protein moieties by the selective binding of phosphate as well as the formation of fluoridated hydroxyapatite and fluorapatite give rise to an increase in the bone-to-implant bond strength, which may be of value in osseointegrated technology.

# Effects of fluoride-modified titanium surfaces on osteoblast proliferation and gene expression

**Isa, Z.M.**
**Schnieder, G.B.**
**Zaharias, R.**
**Seabold, D.B.**
**Stanford, C.**

**Int J Oral Maxillofac Implants**
2006;21, 203-211

**Purpose:** Implant surface topographies which have been shown to influence the differentiation and proliferation of osteoblasts, and the upregulation of transcription factors responsible for the expression of bone matrix formation genes. The purpose of the current study was to evaluate how the application of fluoride to a well defined rough surface affects these factors.

**Materials and Methods:** Titanium discs were treated with either titanium grit blasting with 25 µm particles (TB, TiOblast™) or titanium grit blasting followed by treatment with dilute hydrofluoric acid (TBF, OsseoSpeed™). An additional group of extra rough discs blasted with 125 µm particles were also prepared (ER, extra rough).

All surfaces were studied for comparative topography under scanning electron microscopy (SEM).

Discs were seeded with micromass cultures of human embryonic palatal mesenchymal cells with 50,000 cells/10 µL and left to grow for 72 hours, at which time SEM was used to study cell attachment and morphology on the TB and TBF surfaces. Tissue culture plastic (TCP) was used as a control.

Cell proliferation was evaluated at 1, 3 and 7 days, respectively.

Alkaline phosphatase (ALP) activity was analyzed using a commercial kit and a KC4 microplate data acquisition software, to measure the phosphate concentration per culture (pmol/750 µL).

In addition to this, expression of ALP, core binding-factor- 1 (Cbfa1), osterix (Ox), type I collagen (Col I), bone sialoprotein (BSP II) and osteocalcin (Oc) were analyzed on cells from all rough surfaces using real time PCR strategies performed in 96-well Optical Reaction Plates in an ABI Prism 7700 Sequence Detection System. Statistical analysis was performed using one-way ANOVA with Tukey's Multiple Comparison test.

**Results:** The SEM revealed all surfaces to have an isotropic topography with the TB being the smoothest and the TBF and ER having similar topographies. At high magnification (x10,000) the TBF demonstrated secondary nano-pores.

After 72 hours there was evidence of cell spreading with flattened cells on all surfaces.

ALP activity was significantly lower for TCP compared to all titanium discs, but more so compared to TBF and ER, at days 3 and 7 ($p < 0.001$). However, there was no significant difference between the different titanium groups (at 3 and 7 days).

With respect to cell proliferation, all discs demonstrated a progressive increase in cell numbers, but by day 3 TCP the smooth control surface demonstrated a significantly higher number of cells when compared to all 3 rough surfaces, ($p < 0.001$). There were no significant differences between the TBF and ER surface. By the end of the week TB and TCP were comparable but TBF and ER demonstrated a net reduction in cell numbers by 20%, ($p < 0.001$) compared to TB and TCP.

With respect to gene expression TBF demonstrated a significant increase in Cfba1 compared to the other titanium surfaces at 7 days, ($p < 0.01$), doubling between days 3 and 7. Osteocalacin also increased from day 3 to 7 for all surfaces, while the levels for the other gene expression markers were the same for all surfaces at all time points.

**Discussion and Conclusions:** In the current study smoother surfaces were shown to optimize cell proliferation, however the application of fluoride ions appeared to optimize the upregulation of Cfba1, a transcription factor that is essential for the maturation and differentiation of mesenchymal stem cells into osteoblasts. Other factors such as cell spreading and ALP activity were comparable between titanium surfaces. This suggests the OsseoSpeed surface may be better disposed to support and promote cellular differentiation and potential to enhance osteogenesis.

# Immediate functional loading of implants in single tooth replacement: a prospective clinical multicenter study

**Donati, M.**
**La Scala, V.**
**Billi, M.**
**Di Dino, B.**
**Torrisi, P.**
**Berglundh, T.**

**Clin Oral Impl Res**
2008;19:740-748

Single-tooth implants have been variously reported to show high success rates both when benefitting from a delayed period of healing for osseointegration and when immediately temporized but without immediate functional loading. Only few studies have presented data on immediate functional loading of single-tooth implants (STI).

In conjunction with immediate loading of implants there has been data presented on the benefits of using an osteotome technique for lateral bone condensation to increase peri-implant bone density and the bone-to-implant contact thereby increasing primary implant stability.

**Purpose:** This immediate load study aimed to compare the use of an ostetome and drilling protocol for the placement of STIs (Astra Tech 4.0 mm and 4.5 mm ø) in a prospective randomized controlled manner.

**Materials and Methods:** Seventy male and 81 female patients with good general health were enrolled to the study. Smokers represented 23% of the study population with 11% smoking > 10 cigarettes per day. These patients were evenly distributed amongst the groups. All patients had one tooth missing for at least 3 months, with healthy adjacent teeth. A minimum criterion of 20 Ncm was required as an insertion torque and no indication for grafting was allowed. Patients were randomly allocated to one of three groups. Group 1 acted as control (n = 57) where implants were inserted using a standard drilling protocol according to manufacturer's recommendations, submerged for undisturbed healing, and exposed after 3 months for restoration and functional loading. In group 2 (n = 50) patients also benefitted from the same standard drilling protocol but implants were placed into immediate functional load while in group 3 ( n = 54) osteotomy preparation was via a modified technique using first a 2.5 mm diameter drill followed by osteotomes of increasing diameter to widen the preparation, with implants placed into immediate functional load.

In order to fulfill the requirement of immediate functional loading for groups 2 and 3, an impression pick-up of the implant was made at the time of surgery and a customized abutment and temporary acrylic crown fabricated within 24 hours. Definitive abutments were tightened to 20 Ncm and the temporary crown cemented with Temp Bond. Crowns were placed into centric occlusal contact. After 3 months the implants in the control group 1 were exposed and restored with customized abutments and temporary acrylic crowns. After a further 3 months of functional loading all implants were subject to new impressions and definitive ceramo-metal crowns were delivered.

Patients were recalled at 3 and 12 months for assessment of plaque, probing depth and mucositis scores as well as measurement of the width of keratinized tissue and the papilla length on the mesial and distal of each implant-retained crown.

Standardized intra-oral radiographs taken with a paralleling technique were evaluated by an experienced, blinded radiologist at baseline (insertion) and at 3 and 12 months follow-up to assess the level of the marginal bone relative to the implant-abutment junction. Comparisons between groups were analyzed statistically.

**Results:** Three implants in group 3 failed to osseointegrate (5.5%), while one implant in group 2 failed to integrate (2%). Periodontal parameters were comparable between the groups except for probing depth of 4–5 mm on the distal aspect of group 1 implants which was significantly higher than for groups 2 and 3, $p < 0.05$.

When comparing radiographs there was a notable difference between group 3 and the other two groups with less marginal bone loss, although this did not reach significance. However when considering the frequency of implants which lost > 1.0 mm there was a significant difference between groups 2 and 3 compared to the control group 1, $P = 0.01$. Additionally there was a significant difference in the outcome for 4.0 mm ø implants compared to 4.5 mm ø, in favor of the former which showed less bone loss, $p < 0.05$. When considering treatment protocol and implant diameter as co-variables the analysis revealed a highly significant difference for increased bone loss at 4.5 mm ø implants placed using a conventional surgical protocol, $p < 0.01$. Other variables such as sex and smoking status had no influence, while location was influential, $P = 0.04$.

**Discussion and Conclusion:** Until now no data appears to be available using both an osteotome technique and immediate functional loading for single tooth implants. The data in the current study is broadly comparable with that of other studies, in that the outcome measures from clinical and radiographic parameters are similar to that achieved with a conventional protocol. In the current study implants lost the majority of bone between baseline and 3 months with little additional bone loss thereafter. This too is in agreement with previous studies. The finding that more bone loss was observed at 4.5 mm ø implants is not currently explained, although one can postulate about the influence of primary stability issues and implant geometry, however the marginal bone levels recorded at the 4.5 mm ø implants are similar to those recorded by Cooper and Norton for early and immediate restoration protocols.

The higher failure rate of implants subject to immediate loading is of concern, in particular for 5.5% in group 3 where an osteotome technique was used. It has been proposed that this technique results in trabecular fractures which do not occur when using a drilling protocol. This may require further consideration.

# A 24-week prospective study comparing the stability of titanium dioxide grit-blasted dental implants with or without fluoride treatment

**Geckili, O.**
**Bilhan, H.**
**Bilgin, T.**

**Int J Oral Maxillofac Implants**
2009 ;24(4):684-688

The application of moderately rough surfaces along with other macro- and micro-topographical changes to implants surfaces and design have resulted in an enhanced rate of osseointegration to improve the early stability of the implant. Recently so-called nanotechnology has been applied to implant surfaces to further enhance this early stability and to speed up the rate of bone formation to yield an interface with higher shear strength. The use of a fluoride modified titanium grit-blasted surface (OsseoSpeed™, Astra Tech) has shown promise in in vitro and animal experimental studies in this regard but little clinical data exists to support this contention.

**Purpose:** To compare fluoride-modified (FM) and unmodified (UM) titanium grit-blasted implants with regard to early stability as measured by resonance frequency analysis (RFA) in a clinical prospective cohort over a 24-week period.

**Materials and Methods:** Twenty-seven systemically healthy edentulous patients seeking mandibular overdenture therapy were enrolled to the study. Patients received 2 dental implants in the mandibular canine positions, one FM (OsseoSpeed,) and one UM (TiOblast™, Astra Tech) placed on the left and right sides respectively and always the same dimension 4.5x13 mm. Surgery was performed according to manufacturer's protocol under antibiotic prophylaxis. All implants benefitted from transmucosal healing by connection of a healing abutment at the time of implant placement and tissues were sutured around each abutment. No denture was worn for one month after which a relined conventional denture was provided. Two weeks later dentures were connected to their respective implants via ball or Locator abutments.

Resonance frequency analysis (RFA) were performed at time of implant placement and then at weekly intervals from 1 to 6 weeks and at 12 and 24 weeks post-op using a calibrated magnetic peg device (Smartpeg Type 7, Integration Diagnostics) and the Ostell Mentor RFA analyzer (Integration Diagnostics) to record Implant Stability Quotient (ISQ) values. Results were subject to statistical analysis by analysis of variance and paired sample t-test to evaluate the presence of any differences between the implant surfaces

**Results:** All implants osseointegrated. There were no statistically significant differences in ISQ values at baseline for the two groups with means of 75.7 + 9.6 (UM) and 75.5 + 8.9 (FM). There were no significant changes in ISQ for FM implants while there was a significant decrease in ISQ values for UM implants to week 2 (70.8 + 16.9) with a subsequent rebound in values at week 3 (79.6 + 5.4). There were no significant differences between the groups at each time interval throughout the study period.

**Discussion and Conclusion:** RFA has been shown to provide insight into the stability of an implant such that very low ISQ values can be interpreted as evidence for an implant to be at risk of failure. Furthermore such vulnerable implants have been shown to demonstrate remarkable recovery in ISQ values when protected from functional loading or conditioned with progressive loading protocols.

At time of placement stability is derived purely from a mechanical relationship and values of 75 ISQ are typical and this study corroborates these findings. Thereafter early decreases in ISQ have been reported which coincide with the early remodeling that takes place at the bone-to-implant interface. This relationship was certainly reflected in the UM implant group in this study which demonstrated a significant decrease in ISQ values for the two weeks following implant placement. However no such decrease was noted for the FM implant group whose ISQ values during that period were notably if not significantly higher than for the UM implants.

It is possible that in other regions of the mouth where the over-riding density of bone is lower that differences may be more noticeable, there is also a need for greater sample sizes with randomization of implant position which was lacking in the current study.

Nonetheless it can be concluded from the current study that the application of fluoride modification may further enhance osseointegration and lead to greater stability for the implant during the vulnerable early healing period.

# Three-year post-loading outcomes with MicroThread OsseoSpeed dental implants placed in the posterior maxilla

**Stanford, C.**
**Johnson, G.**
**Fakhry, A.**
**Aquilino, S.**
**Gratton, D.**
**Reinke, M.**
**Asmussen, C.**

**Appl Osseointegration Res** 2008;*7*:49-57

It has been established that bone volume and density can variously affect primary implant stability and implant success rates. In particular it has been shown that higher failures rates can be expected in the posterior maxilla where bone density is often low. In an effort to address these problems the use of osteotomes for sinus lift procedures is said to increase both bone volume by increasing height, as well as density by the lateral compaction of bone trabeculae. However there is also data which suggests this may damage the bone resulting in delayed healing and crestal bone loss.

With the application of nanotechnology and the recent introduction of fluoride modified, moderately roughened surfaces (OsseoSpeed™), which have been shown to have an affinity for up-regulating the activity of osteoblasts and the expression of key genes responsible for the production of mineral matrix, it is proposed that implants with these new surfaces can demonstrate high success even in posterior maxilla.

**Purpose:** This study aimed to present 3-year data for OsseoSpeed implants placed in the posterior maxilla restored using a rapid loading protocol.

**Materials and Methods:** Twenty patients with missing maxillary molars and premolars were enrolled to the study if the residual bone height was < 5 mm in height to the sinus floor and < 6 mm in width. All implants were placed using an osteotome technique and benefitted from transmucosal healing with connection of a Uni-Abutment at time of surgery. All implants were assessed for primary stability using resonance frequency analysis (RFA) to measure the implant stability quotient (ISQ). After 6 weeks of unloaded healing for osseointegration all implants were restored and placed into functional occlusion with a temporary acrylic restoration. This was converted to a definitive prosthesis at one year. Clinical parameters were scored for plaque, gingival index, implant mobility, and bleeding on probing at 4, 8, 12, 26, and 52 weeks and annually thereafter, along with repeated measurements of ISQ.

Radiographic analysis was performed by taking standardized intra-oral radiographs at implant placement, 3, 6, 12, 24 and 36 months post-loading. Images were digitized and bone levels measured to within 0.1 mm by an independent radiologist.

**Results:** A total of 59 implants were inserted into bone graded as quality 4 in 56% of sites, and quality 3 in 34% of sites according to surgeon interpretation. 34 implants were placed in association with an internal sinus lift to increase bone height an average of 4.1 mm. The most common implant length was 11 mm with 27% being shorter that 10 mm. Two implants failed within the first 5 months and another one failed after nearly 2.5 years to yield an overall survival rate of 95%. In 6 subjects loading was delayed due to lack of implant stability even after 6 weeks, however all these implants still went on to osseointegrate. ISQ values were seen to change with time during the first year of loading but not thereafter, $p < 0.05$. The increase was more marked for implants placed in types 3 and 4 bone.

Regarding marginal bone data, the majority of bone loss occurred in the first year and stabilized thereafter. The mean marginal bone loss was -0.12 mm +/- 0.37 mm at the mesial side and -0.25 mm +/- 0.54 mm at the distal side. 80% of all implants demonstrated minimal bone loss over time.

**Discussion and Conclusion:** The literature has shown that the use of osteotomes can increase primary implant stability and this was supported by the current study. However the use of an implant with specific design features aimed at maintaining crestal bone may be necessary to prevent crestal bone resorption seen when using this technique, especially in the posterior maxilla. However bone maintenance was apparent in 80% of this study sample. The higher bone loss noted distally is unexplained but is a phenomenon reported elsewhere (Norton, 2006). Current data further support the widely published maintenance of marginal bone seen with the Astra Tech implant.

# MicroThread™



MicroThread™ is the minute thread design on the neck of the Astra Tech implants, introduced as early as 1991. Scientific articles present the ability of MicroThread to ensure positive biomechanical bone stimulation and to maintain marginal bone levels in the long term. Summarized on the following pages, you will find articles about the continuous follow-up of the MicroThread.

## Pre-clinical



## Clinical



*To read more, please see 11, 34, 50, 62, 64, 67*

# Tissue characteristics at microthreaded implants: an experimental study in dogs

**Abrahamsson, I.**
**Berglundh, T.**

**Clin Impl Dent Rel Res**
2006;8, 107-113

**Purpose:** A degree of crestal bone loss is well established particularly within the first year of function as well as a small but measurable on-going bone loss thereafter. However in the case of an implant with a smooth conical collar it has been reported that marginal bone loss is excessive and that this might be due to the geometric design of the implant. However data that has been gathered with the Astra Tech 4.5 mm implant would seem to demonstrate excellent bone maintenance, casting doubt on the theory that it is related to geometry. In the case of the Astra Tech implant it would appear that it might be related to the surface roughness and in particular to the MicroThread™ design of the collar. This study therefore set out to compare marginal bone response to implants with and without MicroThread on the collar.

**Material and Methods:** Mandibular premolars were extracted from six beagle dogs three months prior to implant installation, bilaterally. At time of implant insertion one test implant with microthreading and 2 control implants without microthreading were randomly inserted according to manufacturer's protocol with the implant/abutment junction (IAJ) being placed at the crest of the bone. All implants benefited from 3 months submerged healing prior to exposure and abutment connection. After a further 3 months, fixed gold prostheses were secured to the abutments by screw-retention. In the opposing jaw fixed prostheses were cemented to previously prepared maxillary canines and premolars to provide appropriate occlusal function. At implant exposure and prosthesis insertion follow-up radiographs were taken and again after 10 months of functional loading. All radiographs were taken in custom holders using a paralleling technique and images were digitized and measurement carried out on the mesial and distal surfaces of each implant.

At the end of the study period all animals were sacrificed and implants removed *en bloc* for histological processing. Ground sections of 20 µm thickness were prepared, two from the mesio-distal and two from the bucco-lingual planes and stained with toluidine blue. Histometric evaluations were undertaken to measure percentage bone-to-implant contact (%BIC) of the neck portion, as well as the entire length of the implants, percentage bone density (% BD), and linear measurements between the landmarks: Mucosal Margin (MM), Bone Crest (BC), apex of Junctional Epithelium (aJE), and the Implant-Abutment-Junction (IAJ).

**Results:** In only one implant healing was compromised due to the formation of a small abscess leading to an infrabony defect. This site was excluded from the analysis.

Radiographic measurements revealed a total mean bone loss, measured from the IAJ, of -0.19 mm for control implants versus +0.05 mm for test implants. Bone levels were principally affected between insertion and abutment connection and then again after functional loading but only within the control group. These differences did not reach significance.

The % BIC measured at the neck of test implants was 81.8% compared to 72.8% for control implants, ($p < 0.05$) but overall % BIC was similar when measured over the entire implant length. The % BD varied for both test and control sites between 78.0% and 80.2%. Linear measurements revealed a longer distance of MM-BC and for IAJ-BC for control implants with MM-BC being statistically longer, 3.45 mm compared to 3.09 mm, ($p < 0.05$).

**Discussion and Conclusions:** In the current study there was a clear radiographic and histologic finding that test implants supported bone closer to the IAJ with a stable marginal bone level which remained at or even slightly above the microgap. These findings are in accordance with clinical results previously published.

It was of particular interest to note the statistically significant increase in % BIC for the neck portion of the test implants, compared to the entire implants, which for their remaining length were essentially the same. Given that all implants in the current study were loaded for an equal length of time it can be deduced that within the neck portion of the test implants the microthreading in some way enhanced and optimized osseointegration, encouraging a higher % BIC and greater marginal bone stability.

# The implant neck: smooth or provided with retention elements. A biomechanical approach

**Hansson, S.**

**Clin Oral Impl Res**
1999;10, 394-405

**Purpose:** This study set out to establish the influence on peak bone stress at the bone-to-implant interface by providing retention elements along the entire length of the implant neck, and to also evaluate the impact of bi-cortical fixation and implant axial stiffness, which have also been shown to help in reducing peak bone stresses.

**Materials and Methods:** Calculations were made using finite element analysis. In order to obtain sufficient accuracy, initial data was calculated from a 3-dimensional (3-d) model of a 72 mm long uniform section of a mandible, built up with 8 node cubic elements, in order to evaluate its elastic behaviour. Data from this model was then transferred into a simpler axisymmetric model built up with 4 node square elements. This axisymmetric model was then adjusted to ensure that relative displacement of upper and lower cortices under a 200 N centrally located load was similar to that obtained in the 3-d model. Certain assumptions were incorporated into the modelling of the bone to allow for its viscoelastic behaviour and to avoid the formation of high peak stress artifacts which were seen to occur at singular points. It was also assumed that for a smooth implant surface only compressive stresses would be resisted, compared to compressive and shear stresses for a surface provided with retention elements.

Into this axisymmetric model a 3.5 mm diameter titanium implant was inserted, built up with 4 node elements and with appropriate information on the modulus of elasticity and Poisson's ratio for titanium. The width of the central bore was altered so that the wall thickness varied between 0.3–0.8 mm which in turn would affect axial stiffness of the implant and its surface was either modelled to be smooth or rough by the incorporation of retention elements, all the way to the top of the implant. Additionally, variations in thickness of the cortical bone were modelled and the implant length was varied to allow for uni- and bi-cortical fixation.

A 1000 N vertical load was applied evenly to all upper implant nodes and the influence of surface character, wall thickness and the presence of uni- or bi-cortical fixation was calculated with regards to the peak interfacial bone stress.

**Results:** When considering the influence of surface characteristic for implants with bi-cortical fixation, and a wall thickness of 0.6 mm, peak interfacial shear stress reduced from 80.6 MPa to 29.6 MPa when the neck was characterized with retention elements. Indeed in all calculations there was always an approximate 60 to 80% decrease in peak stress when the implant neck was characterized with retention elements. An increase of wall thickness from 0.3 to 0.8 mm decreased peak stresses by only 10 to 20%. The influence of uni- or bi-cortical fixation was similar.

**Discussion and conclusion:** The majority of implants have a smooth cervical portion around which significant bone loss has been reported, particularly for those with a long conical shaped neck. However Palmer et al., have reported remarkable maintenance of marginal bone around similarly shaped implants provided with retention elements. It has been postulated that with a smooth neck the bone does not partake in distributing axial load and suffers from atrophy according to Wolff's law. By contrast the interlock afforded by retention elements allows for the axial load to be dissipated via interfacial shear which has been shown to be a critical stressor.

It can be concluded that the provision of retention elements (micro-architecture and/or micro-thread), an increase in axial stiffness of the implant and bi-cortical fixation will all enhance the performance of an implant to resist higher axial loads.

# The implant thread as a retention element in cortical bone: the effect of thread size and thread profile: a finite element study

**Hansson, S.**
**Werke, M.**

**J Biomechanics**
2003;36, 1247-1258

**Purpose:** The purpose of this study was to evaluate the effect of different thread profiles and dimensions on the interfacial bone stress of an idealized axially loaded implant using finite element analysis (FEA).

**Materials and Methods:** The Ansys (V5.0) program was employed for the FEA utilizing the theory of elasticity. A 3.5 mm screw shaped implant of infinite length (c.f. Astra Tech) was model in cortical bone with the threads modelled as a bead whose profile and dimension could be varied. Thread profile parameters were depth (D), top radius of curvature (Rt), bottom radius of curvature (Rb) flank angle (P), and the straight section between the threads (S). The length of the base of the thread was designated (L).

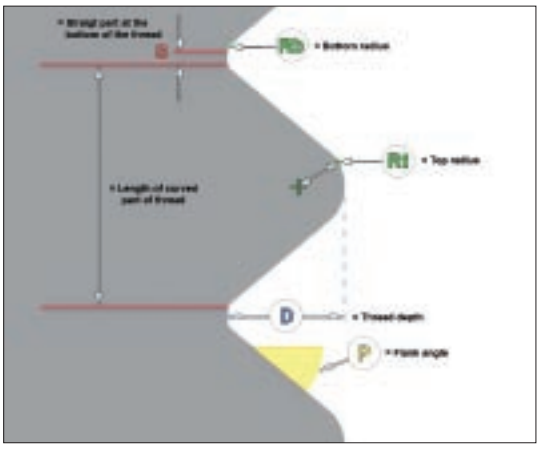


A 100% bone-to-implant contact was assumed permitting frictionless sliding and only compressive stresses transferred between implant and bone. The bone was modelled to be isotropic and homogenous with a Poisson's ratio of 0.3. Test analyses were performed to confirm that a higher than normal modulus could be applied without affecting the calculated stresses. This was necessary to avoid the abruptness of stiffness to complete rigidity, which had to be bridged by the contact elements between the implant and bone. An axial load of 5 N/mm x implant length was applied and the data captured was the peak tensile stress and the peak compressive stress in the bone as a function of the values of the differing thread profiles. The element mesh was made up of 1129 elements, each comprising four nodes. Each node had two degrees of freedom.

**Results:** In all the calculations for the different thread profiles the peak tensile stress was located outside the top of the thread. The peak compressive stress was located on the lower slope of the top radius of curvature except for large flank angles combined with long value for S, when the peak compressive stress was located close to the bottom of the thread flank.

Using convergence analysis it was determined that a thread depth of 0.1 mm was as effective as a thread depth of 0.4 mm. As such very small threads could in fact prove remarkably effective at distributing functional stresses. In addition a low ratio between the top radius of the curvature, Rt and thread depth, D should be avoided since deep sharp threads gave rise to deleterious stress concentrations.

With regard to the distance between threads it appears that the influence of this parameter is dependant on other factors, as such for a continuous thread profile where the distance S is extremely small, the Rt and P influence the stresses. In such a case a value for Rt equal to 0.4–1.0 times the thread depth and a value for P equal to 40–60 degrees yields low values for tensile stress. When the threads are separated and the distance S is large the flank angle should be approximating 0 degrees, since for large flank angles high tensile stresses are recorded where the threads are separated by an increasing distance S.

Finally with respect to Rb it was assumed that a value 0.1 times the thread depth was optimal since the stresses were not located in this area.

**Discussion:** In the current study the model of a stiff, infinitely long, axially loaded implant embedded in homogenous, isotropic, cortical bone, with a frictionless interface and 100% bone-to-implant contact is far from clinical reality. However, the model was established to allow the distribution of stress in the bone to be identical outside all threads thereby allowing a comparison between threads of different size and profile. In addition the attempt to understand the pure effect of thread profile and dimension on bone stresses warrants this idealistic approach. Its findings then require clinical validation.

The FEA results indicated that the thread profile did influence the stress peaks in bone. In addition it appeared that subject to a favourable profile, very small microthreads were equally as effective as large threads. In addition it could be stated that a small value for the top radius of the curvature, Rt, is to be avoided and a large value for the section between the threads, S is unfavourable for most thread profiles as is a large value for the bottom radius of the curvature, Rb.

# Effects of implant design and surface on bone regeneration and implant stability: an experimental study in the dog mandible

**Rasmusson, L.**
**Kahnberg, K.E.**
**Tan, A.**

**Clin Impl Dent Rel Res**
2001;3, 2-8

**Purpose:** The current study set out to investigate whether an alteration to implant surface texture by means of grit-blasting and/or the addition of retention elements as a MicroThread™ would influence the healing of marginal bone defects and the associated implant stability.

**Materials and Methods:** Three implant types were employed in the study, these were Brånemark System 3.75 x 8.5 mm (BS) which were machine prepared, and Astra Tech ST 4.5 x 9 mm (ATST) and Astra Tech MicroThread™ 4.0 x 9 mm (ATM), which both present with a titanium grit-blasted surface and so-called MicroThread™ in the coronal third of the implant. The ATST implants also present with a tapered coronal collar.

One of each implant was immediately inserted into the socket of either P2 or P3 premolars, which were extracted bilaterally in each one of six greyhound dogs, under anaesthesia. Crestobuccal bone defects measuring 3 x 3 mm were created adjacent to the implants on one side only (test side), with the contralateral alveolus being left intact to act as control. A transducer was attached to all implants in order to measure their baseline resonance frequency (ISQ value) to assess their interfacial stiffness, before flaps were repositioned and implants benefited from submerged healing for 4 months.

After the healing period a second ISQ value was recorded. Thereafter all animals were sacrificed and implant specimens were removed *en bloc* and fixed in formalin. Specimens were embedded, sectioned and ground to 10 µm prior to staining with toluidine blue 1% and Pyronin-G. Histomorphometric evaluation was carried out on both sides of each specimen to measure the percentage bone-to-implant contact (BIC), the percentage bone area in all threads (BA), and the distance from each implant's reference point to the most coronal bone contact.

**Results:** Healing was uneventful and all implants showed some degree of bone regeneration at the defect sites. When considering the ISQ values there was a typical increase in stiffness for all implants as a result of osseointegration in both test and control groups, which tended to be more significant for ATST and ATM. In addition the change in ISQ at 4 months compared to baseline for test implants compared to control implants reached statistical significance for both Astra Tech implant types ($p < 0.05$).

Histomorphometry revealed a statistically significant increase in mean BIC for Astra Tech implants compared to the Brånemark implant with 4-month values measuring 51% (ATM) > 47.4% (ATST) > 23.6% (BS) for test and control implants combined. Mean BA measured 38.9% (ATST) > 36.7% (ATM) > 32.5% (BS) for test implants and 42.1% > 41.3% > 34.8% for control implants respectively.

The mean distance from each implant's reference point to the most coronal bone contact was significantly longer for the Brånemark implants compared to the Astra Tech implants ($p < 0.05$) measuring 2.70 mm (BS) 2.20 mm (ATM) > 2.18 mm (ATST).

**Discussion:** The finding in this study that implants with a roughened surface result in an increased BIC is supported in the literature from human, animal and *in vitro* studies. It is also interesting to note that the distance to the most coronal bone at defect sites was notably shorter for these same roughened implants. This may also be related to the MicroThread. Increase in ISQ values was mostly attributable to osseointegration, however some notable relative increase in ISQ was seen for roughened implants. Whether new bone filling in the defects provides any additional stability can not be verified. Data would suggest this to be unlikely, either due to lack of integration or possibly due to its immature structure.

# Effect of microthread on the maintenance of marginal bone level: a 3-year prospective study

**Lee, D.W.**
**Choi, Y.S.**
**Park, K.H.**
**Kim, C.S.**
**Moon, I.S.**

**Clin Oral Impl Res**
2007;18, 465-470

**Purpose:** Maintenance of the peri-implant marginal bone is not only seen as essential for functional support of the implant but today it is identified as the key to the maintenance of a healthy and esthetic peri-implant mucosa, which is central to treatment success. Previous studies have identified that bone initially undergoes resorption settling typical 1.5 mm below the implant shoulder at the first thread. It has been proposed that such bone loss can be prevented by the provision of retention elements at the top of the implant in the form a rough microtextured surface (RMS) and/or the provision of MicroThread™ (MT). Within the Astra Tech system implants have been presented with both RMS and a combination of RMS with MT. This might explain the variable data on marginal bone levels, but to date no direct comparison has been made. As such this study was established to compare two RMS implants, one with and one without MT, to determine the impact on the long-term marginal bone levels.

**Materials and Methods:** Seventeen patients requiring implant therapy for replacement of at least two missing adjacent teeth were enrolled in the study. Subjects had to complete a periodontal program and demonstrate good oral hygiene maintenance. Implants were selected to be RMS (Astra Tech, 4.0 mm Ø, TiOblast™) or RMS/MT (Astra Tech, 4.5 mm Ø, ST) and both types were placed in a randomized order in all patients. A two-stage surgical protocol was utilized and prostheses were delivered 3 months after exposure.

Patients were reviewed every 3 months and an assessment was made of pain, implant stability, gingival inflammation and superstructure complications annually along with evaluation of intra-oral radiographs taken in a Rinn device and with a standardized technique. Images were digitized and a measure was made on the mesial and distal aspects from a fixed reference point at the base of the coronal bevel to the first point of bone contact. Any bone above the reference point was given a value of zero. Results were subject to statistical analysis using Wilcoxon's signed-rank test at the $p < 0.01$ level.

**Results:** A total of 34 implants were inserted, of which 22 were in the maxilla and 12 were in the mandible. All implants osseointegrated and all prostheses were successfully delivered without complications or symptoms up to the 3-year recall. The mean marginal bone loss measured 0.14 mm, 0.21 mm and 0.24 mm for RMS/MT implants at the 1- , 2- and 3-year recalls respectively. These values were consistently lower than for RMS-only implants where bone loss measured 0.28 mm, 0.48 mm and 0.51 mm respectively. Differences were highly statistically significant at all time frames, ($P = 0.001 – 0.002$). In addition there was a notable trend to indicate the rate of bone loss was lower for those implants which benefited from a MicroThread™, particularly from baseline to the end of the first year, ($P = 0.002$). The amount of bone loss was significantly higher for both implants when comparing the first year to those subsequent.

**Discussion and Conclusion:** Many factors have been identified as possible contributors to marginal bone loss. These include the presence of a machined surface without retention elements, the establishment of a biologic width, the disruption of the soft tissue interface by utilizing healing abutments, implant geometry the presence or absence of periodontal disease. In the current study both implants presented with an identical RMS to the top of the implant and both utilized an internal 11° conical interface which should in theory dictate identical biologic width requirements. In addition the use of healing abutments and a two-stage approach was identical for both implant types ruling out these factors as confounding variables. While it is recognized that the implants varied in diameter by some 0.5 mm, this has been shown in a previous study not to have influenced bone loss. As such it is believed that this study allowed a true interpretation of the influence of the MicroThread on the Astra Tech ST implant, although it is accepted that patients will have had different periodontal susceptibilities.

Although, early biomechanical resistance to initial loading within the first year could not be verified, this study clearly showed that implants that benefited from MicroThread demonstrated a significantly lower marginal bone loss over a 3-year period compared to implants without MicroThread.

# Multiple single-tooth implant restorations in the posterior jaws: Maintenance of marginal bone levels with reference to the implant-abutment microgap

**Norton, M.**

**Int J Oral Maxillofac Implants**
2006;21, 777-784

**Purpose:** There has been increasing interest in the role of the implant and abutment microgap and its influence of the establishment of a biologic width across the interface resulting in marginal bone loss of up to 2 mm. Other proposals for crestal bone loss include joint micro-movement, implant geometry and the nature of the implant surface topography.

The present study considered the outcome for maintenance of crestal bone when restoring implants as multiple adjacent single-tooth units in the posterior jaws. In addition all prosthetic complications were recorded.

**Material and Methods:** 54 patients consecutively enrolled for replacement of 2 or more adjacent teeth posterior to the canines were included in the study. A 4.5 mm diameter tapered implant (Astra Tech ST) was selected as the principle implant for use in the study with either a 4.0 mm or 5.0 mm implant diameter available where circumstances dictated. It was part of the study protocol for treatment to be executed in a transmucosal one-stage manner. All implants were placed at or just below the crest of the ridge according to manufacturer recommendations. Implants benefited from a 3 to 4 month healing phase prior to connection of the definitive single-tooth abutments and fabrication of the individual ceramometal crowns which were all cemented with Temp bond.

Marginal bone levels (MBL) were measured from the implant-abutment junction to the first crestal bone visible at x8 magnification. Where bone levels were coronal to the junction the score given was 0.0 mm in order to avoid positive bias. The geometry of the implant itself was used to ensure accuracy of measurements.

A statistical analysis was undertaken to determine the presence of any correlation for bone loss with gender, jaw, smoking status as well as comparing mesial vs. distal surfaces.

**Results:** A total of 181 implants were inserted with only one implant removed during the follow up phase of the study, up to 7 years, equating to a 99.4% survival rate. Radiographs of 173 implants were suitable for analysis. The mean MBL for the pooled data from the implant-abutment junction measured -0.65 mm. MBLs by jaw were -0.56 mm for maxilla and -0.7 mm for the mandible, by gender were -0.72 mm for females and -0.53 mm for males, by smoking status were -0.63 mm for non-smokers and -0.77 mm for smokers. The differences were not statistically significant. When comparing mesial and distal surfaces the MBLs measured -0.53 mm and -0.76 mm, ($p < 0.001$). A total of 28 crowns de-cemented over 7.5 years but recurrent de-cementation was rare with only 4 further episodes. Porcelain fracture was reported for 13 crowns. Abutment screw loosening was only reported for 4 screws in 4 separate patients.

**Discussion and Conclusions:** The current study demonstrates the effectiveness of the multiple single-tooth approach when used to replace multiple missing posterior units. Patients reported a high level of satisfaction with the cosmetic and hygienic aspects of the treatment and being individual crowns, retrieval for maintenance was simplified comparative to cumbersome multi-unit prostheses.

The commonest problem was cementation failure which occurred in 17.7% of cases using temporary cement. Given the low risk of screw loosening with the system used (2.2%) it is reasonable to propose the use of stronger cement.

The mean marginal bone loss of -0.65 mm is low when one considers that this was a measure of total bone loss from the microgap including any initial adaptation. This is contrary to what might be expected according to the theory of biologic width. It has been proposed that the influence of joint design, surface topography and medialization of the abutment with respect to the outer edge of the implant may all mediate a positive impact on the maintenance of marginal bone. This is reflected in the frequency of no bone loss which measured 23.1% in the maxilla and 16.7% in the mandible where bone could be seen to have an intimate juxtaposition with the implant-abutment junction.



# Conical Seal Design™

Conical Seal Design™ is the original and scientifically documented conical connection of the Astra Tech Implant System™, creating a strong and stable fit between implant and abutment. Below you will find many references that primarily address the technical questions related to Conical Seal Design.

## Pre-clinical

# Implant-abutment interface: biomechanical study of flat top versus conical

**Hansson, S.**

**Clin Impl Dent Rel Res**
2000;2, 33-41

**Purpose:** The aim of this study was to determine the impact of having a conical versus a flat-top fixture-abutment connection on the induced stress patterns within the bone surrounding an implant with a microthreaded portion, via finite element analysis.

**Material and Methods:** The finite element method is a very powerful mathematical tool used to calculate the stresses in a structure.

An axisymmetric finite element model of the mandible was used, with previously established parameters for elastic constants. The bone and titanium were assumed to be isotropic, having the same elastic properties in all directions. The implant was modeled to represent a 3.5 mm diameter implant with either an 11-degree internal connection or a flat-to-flat connection. Axial stiffness decreased at the apical end to simulate the macrothreads of an implant reducing the overall wall thickness compared to the microthreaded region.

Axial loads of 1000 N were applied to both systems, with either an even load distribution over the surface or concentrated on selective nodes.

Principal stresses in the bone and the interfacial shear stress were calculated on the assumption that there was no fusion between implant and bone, such that the interface could not resist tensile stress. Interlocking between implant and bone was modeled by connecting interfacial implant and bone nodes in a vertical direction resisting shear.

**Results:** Peak interfacial shear stresses measured between 44 and 100 MPa for the flat-to-flat connection becoming progressively worse when the load applied was modeled only on a lateral node contact.

For the conical connection the stresses ranged from 26 to 32 MPa, when applying the same load. In addition the stress distribution patterns were markedly different with load being concentrated at the most coronal margin for the flat-to-flat connection but being more evenly distributed and at a deeper level, on the implant surface in the bone, for the conical connection.

A similar pattern was noted for the principle stresses which ranged from –32.4 to –277.7 MPa and from –8.5 to –103.3 MPa for the two connections respectively. These stresses were compressive in nature.

**Discussion:** While the principal stresses recorded were higher than the interfacial shear stress recorded for both connections, the forces were compressive in nature, which is well tolerated by cortical bone. In this respect the shear stress is considered to be of greater significance.

Furthermore while clinical function of implant supported prostheses will lead to a variety of vectorial loads and moments, it is likely that only the axial loads will result in interfacial shear stresses, and these can be most destructive if the shear strength of the interface is exceeded, leading to slip and fracture of the interfacial tissues.

In the current finite element analysis it was apparent that the induced stresses were reduced by the application of the axial load along the internal conical surface of the implant. This also resulted in a more even and deeper distribution of the stress taking it away from the more delicate marginal region. This would indicate that an implant with a conical interface can theoretically resist a bigger axial load before triggering bone resorption. In gene-ral terms the results also indicate that a favorable stress distribution can be accomplished by a more central and deeper application of the axial load.

# A conical implant-abutment interface at the level of the marginal bone improves the distribution of stresses in the supporting bone. An axisymmetric finite element analysis

**Hansson, S.**

**Clin Oral Impl Res**
2003;14, 286-293

**Purpose:** Previous studies have indicated that a concentration of peak stresses in the crestal bone is responsible for marginal bone loss. Early assumptions that a smooth neck would help to reduce these stresses has proved incorrect since clinical evidence demonstrates consistent bone loss at smooth necks. In contrast the application of retention elements at the neck has been shown to aid stress distribution. In addition it has been suggested that an internal conical implant-to-abutment joint allows for a more apically placed concentration of stresses away from the marginal bone, when compared to a butt joint interface.

The current study utilized a finite element analysis (FEA) calculation to measure and compare peak stresses for 1- and 2-piece implants (1-P, 2-P) modeled with a conical joint configuration and a microthread, with varying wall thicknesses and moduli of elasticity.

**Material and Methods:** An axisymmetric model consisting of four-node elements modeled the upper cortical bone presumed to be in contact with the surface of a load carrying implant. The thickness of the cortex was modeled to be 2.8 mm, with a modulus of elasticity of 15 GPa. The 2-P implant was modeled such that the joint was effectively intraosseous, while the equivalent conical portion modeled in the 1-P implant was placed above the crest of bone, 2 mm coronally. Each set of calculations was repeated for implant wall thicknesses of 0.3 mm, 0.6 mm, and 0.9 mm. An axial load of 100 N was applied. The material (titanium) for the implant was given a modulus of elasticity of 107 GPa. Furthermore at a wall thickness of 0.6 mm, the modulus of elasticity was compared with one of 53.5 GPa, 214 GPa, and one presumed to be infinitely stiff 1.07 $x10^{17}$ Pa. The bone-to-implant interface was assumed to resist compression but not tension or shear.

**Results:** When comparing the magnitude of compressive, tensile and von Mises stresses within the 1-P or 2-P groups for differing wall thicknesses, the data indicated that the only notable differences occurred at the most superior thread in the 2-P implant where increased wall thickness led to increased stress. Elsewhere, differences in wall thickness made little impact on the peak stresses. For differing moduli of elasticity the calculated stresses were also similar within the groups. Again such differences were not-able at the level of the first thread for the 2-P implants.

When comparing the two groups, there was a stark difference regardless of wall thickness or modulus of elasticity, such that the 2-P implants recorded their peak stress deep within bone at the level of the 5th to 9th thread compared to 1-P implants whose peak stress was always concentrated at the first two threads and with a magnitude far greater than any peak stresses recorded in the 2-P group.

**Discussion and Conclusions:** The current model does not reflect reality in so far as it is not 3-dimensional and it idealizes the characteristics of the interface and the bone, which in reality is viscoelastic, heterogeneous, and anisotropic. Nonetheless, the relative comparison of the 1-P and 2-P systems is valid and such relativity can be extrapolated to the clinical reality. Furthermore, the locations of the peak stresses calculated in the current study are in accordance with previously published data.

Certainly the results of this study support the findings of an earlier study that the use of an internal conical joint displaces the location of the peak stresses to a more apical location. This was not altered by the presence of an external microthread. In contrast the placement of the conus supracrestally in a 1-P implant design had a negative effect giving rise to much higher peak stresses in both magnitude and in location at the most crestal threads. However an increase in either wall thickness or modulus of elasticity had the effect of increasing the stresses located more coronally in the 2-P system due to increased implant stiffness. This resulted in higher peak stresses at the level of the first thread, but significantly lower than that calculated for the 1-P implant design.

It can be concluded that an implant which benefits from an internal conical implant-abutment joint, placed within the marginal bone, performs in a superior manner to a 1-P implant where the joint is located supracrestally. Furthermore, the application of microthreads, and careful consideration of implant wall thickness and stiffness will help to yield an implant optimally suited to reduce peak stresses in the crestal bone. Such results have been seen in clinical practice with superlative bone maintenance data reported in the literature for an implant based upon these design features.

# Molecular leakage at implant-abutment connection – in vitro investigation of tightness of internal conical implant-abutment connections against endotoxin penetration

**Harder, S.**
**Dimaczek, B.**
**Açil, Y.**
**Terheyden, H.**
**Freitag-Wolf, S.**
**Kern, M.**

**Clin Oral Inv**
**E-pub 23 July 2009**
DOI:10.1007/s00784-009-0317-x

Peri-implant soft tissue reactions and marginal bone loss are thought to be induced by amongst other things implant-abutment joint instability and microleakage of bacteria and bacterial endotoxins. Such microleakage has previously been demonstrated in two-piece implants where micro-gaps exist at the joint. The advent of tightly fitting internal conical joints has promise since these joints have been shown to eradicate micro-movement and thus it is proposed perhaps microleakage.

**Purpose:** Since endotoxins represent much smaller molecular components than whole bacteria, this study set out to test the presence or absence of endotoxin microleakage in two systems previously shown to benefit from tight internal conical implant-abutment joints.

**Materials and Methods:** The systems under test were the Astra Tech Implant system™ (AT) using a two-piece hollow abutment with abutment screw (TiDesign™) and the ANKYLOS® (AK) system using a one-piece solid abutment (b/3.0/4.0).

All components were heat treated and handled in ultra-sterile conditions in a microbiological cabinet with laminar air flow to avoid external contamination. Eight implants of each system were inoculated with 0.5 µl of lipopolysaccharide endotoxins extracted from Salmonella Enterica at a concentration of 20 mg/ml. The endotoxin was pipetted into the deepest internal aspect of each implant prior to abutment connection and tightening to manufacturer's recommended torque. Assembled units were then agitated in a bath of supernatant at a frequency of 20 motions/min. Samples of supernatant were collected at intervals of 5 minutes, 24, 72, and 168 hours. Implants with endotoxin inoculation for 0 minutes served as control.

The collected sample was then subject to the QCL-1000 chromogenic limulus amebocyte lysate test which allows detection of endotoxin from gram negative bacteria. This is achieved by the use of a spectrophotometer to evaluate any change in optical density of the supernatant which turns yellow (when the chromogenic substance react with endotoxin) at a wavelength of 405–410 nm.

Results for each system and each time point were subject to statistical analysis using one-sided Wilcoxon signed rank tests and the Friedman test, with significance set at the 95% confidence level.

**Results:** In the AK group endotoxin contamination was observed for all samples within 5 minutes of agitation, without exception. In the AT group 3 implants showed no sign of contamination after 5 min and after 72 h still 2 implants showed no signs of contamination. One implant remained contamination free even after 168 h of agitation. There was a direct correlation between agitation time and degree of contamination for both systems. ($p < 0.01$). Significantly less contamination was observed for AT implants at every time point when compared to AK implants, $p < 0.05$.

Discussion and Conclusion: It is conceded that the heat treatment used in the current study to ensure absence of any unrelated confounding contamination of the implant components might have affected the tightness and hence the resistance to microleakage of the internal joints under test. Nonetheless all samples, except one (AT) demonstrated microleakage within the given time frame up to 168 h post contamination.

To avoid external contamination all efforts were made to ensure components and equipment used as well as the experimental set-up were free from extrinsic contamination. If contamination was noted at time 0min (baseline) it was assumed contamination had occurred in error and the sample was excluded from analysis.

Results from the current study concur with previous studies but show the AT implants to yield statistically less microleakage at all sampling points. This may be due to the smaller gap size reported at the conical implant-abutment junction for AT implants (1–2 µm) compared to that for AK implants (4 µm) (Jansen et al 1997).

# An *in vitro* evaluation of the strength of an internal conical interface compared to a butt joint interface in implant design

**Norton, M.**

**Clin Oral Impl Res**
1997;8, 290-298

**Purpose:** The aim of the study was to compare the strength of the fixture/abutment and abutment/bridge cylinder interfaces for implants utilizing a butt joint and a conical joint design.

**Materials and Methods:** The Astra Tech implant and Brånemark implant were used to represent the conical joint and butt joint designs respectively, with units being assembled according to manufacturer's recommendations.

Each implant was screwed into a metal beam at one end, with the abutment or bridge-cylinder being clamped to another beam at the opposite end. In order to assess the strength of the implant/abutment and abutment/bridge cylinder interfaces, the 3-point bending test was utilized, with the application of a known force at right angles to the interface, by means of a screw driven loading device. For each system and each interface, 6 units were tested.

Recordings were made for both the point of first plastic bending, recorded as a 0.3 mm deformation and also maximum bending to failure. The displacements were recorded on a Linear Variable Differential Trans-former (LVDT). Load and displacement were analysed using an appropriate software program.

**Results:** For the implant/abutment interface, the mean moments required to register the point of first plastic deformation was 1315 Nmm and 645 Nmm for the conical joint and butt joint respectively, with a mean moment force of 2030 Nmm and 1262 Nmm to cause failure of each joint. The difference between the moments was highly statistically significant ($p = 0.00010$ and $p < 0.0010$, respectively). Furthermore the coefficient of variance was low confirming the strict homogeneity of both material and design, in both systems, which would suggest that the results would be reproducible in larger sample.

In the Astra Tech system failure did not result in either elongation or abutment fracture, however it is likely that imperceptible vertical hair-line fractures did occur at the neck of the implant. For the Brånemark system there was a notable elongation of the abutment screw with loosening of the joint.

When testing the two systems at the abutment/bridge cylinder interface, the mean moments required to register the first point of plastic deformation were 994 Nmm and 725 Nmm for the conical and butt joints respectively, with a moment force of 1866 Nmm and 1305 Nmm required to cause failure of each joint, which for the Astra Tech system was a fracture of the bridge screw, but for the Brånemark system, the abutment screw was once again seen to be the focus of deformation. Again the differences were statistically significant ($p < 0.010$ and $p = 0.0001$, respectively).

**Discussion:** Biomechanical failure has become the focus of concern with a constant source of data drawing attention to the problems of screw loosening and screw fracture.

Whilst numerous efforts have been made to address this problem, in particular with the introduction of the torque driver, there has been little data published confirming the efficacy of the butt joint or other designs to resist bending moments.

This study has demonstrated that the conical joint is significantly superior to the butt joint in resisting bending moments when tested in the extreme, such as in the 3-point bending apparatus described, and that furthermore the abutment screw is the weakest point in the butt joint design and not the bridge screw, when using the Estheticone system.

# Assessment of cold welding properties of the internal conical interface of two commercially available implant systems

**Norton, M.**

**J Prosthet Dent**
1999;81, 159-166

**Purpose:** The external butt joint is common in implant design with joint connection being dependent on the abutment screw. Data to support this design from an engineering perspective is scant and has been shown to result in joint instability. By contrast the concept of a one-piece conical abutment has been shown to yield high resistance to bending moments, resulting in improved joint stability. However, concern has been expressed that such conical abutments are at risk of "cold welding" making them non-retrievable. This study set out to confirm or refute the presence of cold welding for two commercially available conical abutment designs, utilized in the ITI and Astra Tech (AT) implant systems.

**Materials and Methods:** 5 units of the AT 3.5 mm diameter implant, and 4.0 mm diameter implant allowed a comparison of interfacial surface area, 15.3 $mm^2$ versus 27.9 $mm^2$ respectively. At the same time a comparison of these AT units to 4 units of the ITI system (group 3) allowed a comparison between the 8º (ITI) and 11º (AT) tapers. Additionally all test were run dry and also with components bathed in artificial saliva at 37ºC.

Two test series were performed. The low torque tests, which were deemed clinically relevant, were performed for tightening torques ranging from 4 to 50 Ncm. The high torque series was for torques greater than 100 Ncm and was employed to identify the limits of each system with 3 units eventually torqued to failure to reveal the critical zones. Additionally 2 units in this series were torqued to the maximum prior to failure and then "bench rested" for 10 and 60 minutes to determine any apparent influence of elastic recoil of the material.

Data was subject to statistical analysis to determine any correlation between tightening and loosening torque, whereby a figure exceeding 100% represented an increased torque required to remove the abutment, indicating cold welding. Additionally statistics were used to determine any significant difference between systems tested, and between dry versus wet environments.

**Results:** In the low torque series the trend was for all units tested within the three groups to be loosened at 80–90% of the tightening torque. One or two units exceeded 100% at isolated torque levels, however the correlation between removal torque and tightening torque was highly significant, $p<0.01$, confirming that overall there was no evidence of cold welding. Additionally there was no statistical difference between wet versus dry conditions ($p>0.30$).

For the high torque series new units were utilized. The AT 3.5 mm units failed to achieve a cold weld even at the 200 Ncm level, and even after bench resting. By contrast the AT 4.0 mm and ITI units both demonstrated cold welding of 113% and 104% respectively, as a mean at the 100 Ncm level. Above 100 Ncm the mean values for cold welding actually decreased slightly, notably after bench resting. Failure of the units occurred at a mean of 211, 307, and 200 Ncm for the AT 3.5 mm, AT 4.0 mm and ITI units respectively. The volume of data available for this series was too limited to conduct a separate statistical analysis and was therefore pooled in with the data from the low torque series.

**Discussion and Conclusions:** Considering clinically relevant torques of 20 to 50 Ncm, there was little variation between systems, with a removal torque approximately 85% of the tightening torque, with a strong correlation, $p< 0.01$. This contrasts a previous report indicating a 124% value for the ITI system at 25 Ncm. There was no difference between the results for dry components versus those bathed in artificial saliva at 37ºC.

The high torque series revealed a difference between AT 3.5 mm, where a cold weld was never demonstrated, and AT 4.0 mm achieving a cold weld at 100 Ncm. This suggests that the surface area of the interface is crucial in determining cold welding. There was little difference between the AT 4.0 mm and the ITI units. It should be noted however, that this apparent cold welding might be a reflection of the difference between resting friction and gliding friction, which for metals is always higher. All components failed at levels far in excess of what is achieved clinically.

It can be concluded that for clinically relevant levels of torque, none of the units tested achieved a cold weld.

# Micro-movements at the implant-abutment interface: measurement, causes, and consequences

**Zipprich, H.**
**Weigl, P.**
**Lauer, H.C.**
**Lange, B.**

"Erfassung, ursachen und folgen von mikrobewegungen am implantat-abutment-interface"

**Implantologie**
2007;15, 31-45

*For videotape clips and English abstract see www.kgu.de/zzmk/werkstoffkunde*

**Purpose:** Most of two-component or multi-component implant systems use an implant-abutment connection with a clearance fit. The clinical impact is assumed as high according to the following factors: 1) Implant systems consisting of two or several components are much more widespread than single component systems because they offer a number of well-known clinical and technical advantages. 2) Unconnected crowns in the posterior region are more susceptible to technical failure of the implant-abutment interface. 3) Crestally or subcrestally placed implant-abutment interfaces are frequently subjected to crestal bone resorption following abutment connection. This *in-vitro* study examined the dynamic behaviour of different designs of implant-abutment connections

**Materials and methods:** Abutments were loaded at an angle of 30° with a force of up to 200 N. The distance of the point of force application from the implant platform was 8 mm; the gradation of the force was 0.3 N/ms. The interface of the implant-abutment connection was examined and measured radiographically using a professional high speed digital camera (1,000 images per second).

**Result:** The results showed that, under simulated clinical conditions, complex mechanisms are responsible for the presence or absence of a micro-motion. All implant-abutment connections with a clearance fit exhibit a micro-motion (implant systems: SIC®; Replace Select®; Camlog®; XIVE®; Straumann synOkta®; Bego-Semados®; Straumann massive conical abutment®). Precision conical connections (implant systems: Ankylos®; Astra Tech) show no micromotion.

| Implant | Index | Micro-spalt at 200 N |
|---|---|---|
| Astra Tech | dodecagonal | 0.0 µm |
| Ankylos® | non indexed | 0.0 µm |
| Straumann massive abutment® | non indexed | 0,1-4 µm |
| Bego-Semados® | hexagonal | 0,1-4 µm |
| Replace Select® | 3-positions | 12-16 µm |
| XIVE® | hexagonal | 16-20 µm |
| Straumann synOkta® | oktagonal | 20-24 µm |
| SIC® | hexagonal | 28-32 µm |
| Camlog® | 3-positions | 32-36 µm |

**Discussion:** The potential clinical relevance of these results can at this point only be derived from theoretical considerations. Presumably, the pumping effect caused by the micro-motion plays an important role for crestal bone resorption. It is assumed that the bone is contaminated with liquid contained in the implant.



# Connective Contour™



Connective Contour™ is the unique and scientifically documented contour that increases soft tissue contact zone and volume, created when the abutment is connected to the implant. Connective Contour is also an original key feature of the Astra Tech Implant System™.

The summaries in this section highlight the understanding of soft tissue healing around and esthetics maintained by the Astra Tech Implant System.

## Pre-clinical



## Clinical

# Tissue reactions to abutment shift: An experimental study in dogs

**Abrahamsson, I.**
**Berglundh, T.**
**Sekino, S.**
**Lindhe, J.**

**Clin Impl Dent Rel Res**
2003;5, 82-88

**Purpose:** The aim of this experimental study was to evaluate tissue response following removal of healing abutments and placement of definitive abutments.

**Material and Methods:** The mandibular premolars of 6 beagle dogs were extracted 3 months prior to re-entry for insertion of three 8 x 3.5 mm Astra Tech implants bilaterally. Baseline radiographs were taken immediately after implant placement using a customized device to permit standardization. Cover screws were placed and flaps repositioned for submerged healing. After a further three months an exposure procedure was carried out via incision and flap elevation for removal of cover screws and location of healing abutments in two of the implants (G1 and G2) and a definitive UniAbutment in the third implant (Control). After a further two weeks the two healing abutments were replaced with a UniAbutment (G1) and a Profile BiAbutment (G2). The latter had been prepared in a dental laboratory and then cleaned in an ultrasonic bath and autoclaved. Radiographs were taken again.

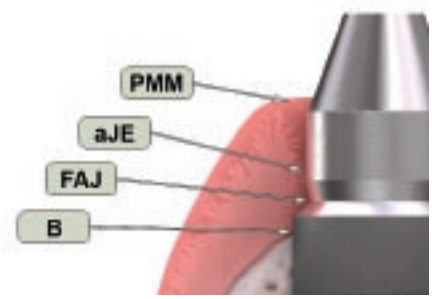


*PMM – Position of the marginal mucosa; aJE – Apical termination of junctional epithelium; FAJ – Fixture/abutment Junction; B – Bone level*

All abutments were subject to a rigorous cleaning regime and then were assessed clinically and radiographically after 3 and 6 months, at which point the animals were sacrificed. Their mandibles were removed *en bloc* to harvest the individual implants for preparation using the fracture technique to create a buccal and lingual tissue portion from around each implant, which were then further subdivided mesiodistally. Each quarter portion was fully decalcified, sectioned to 3 µm and stained in periodic acid-Schiff and toluidine blue. Five sections from each of the four portions were used for histologic and histomorphometric analysis to measure the position of the marginal mucosa (PMM), the apical termination of the junctional epithelium (aJE), the marginal bone-to-implant contact (BIC), the level of the fixture/abutment junction (FAJ) and the distances between these various landmarks. In addition the location and size of any inflammatory lesion was measured. Finally the content of collagen, vessels, fibroblasts, and residual tissue was calculated in a defined peri-implant zone.

**Results:** All implants osseointegrated, and the clinical examinations revealed a high degree of plaque control at all surfaces. Baseline marginal bone levels were similar for all three groups. Initial bone loss measured 0.7 mm to 0.9 mm after the first 6 months of plaque control. These changes were not significant between the control group and the two test groups, G1 and G2.

For histometric measurement the distances between various levels was comparable with PMM-B ranging from 3.11 mm to 3.25 mm, PMMaJE ranging from 1.72 mm to 1.76 mm, aJE-BIC ranging from 1.35 mm to 1.48 mm and FAJ-BIC ranging from 0.72 mm to 1.00 mm. The differences were again not significant. However the size of the inflammatory lesion was significantly bigger by area in the G2 group (0.64 $mm^2$) compared to controls (0.07 $mm^2$), ($p < 0.05$) and the G1 group (0.15 $mm^2$),($p < 0.05$). This infiltrate was well defined and consistently seen in the connective tissue compartment at the level of the FAJ and for G2 implants it extended lateral to the barrier epithelium. There was no significant difference between the proportion of vessels, collagen, fibroblasts and residual tissue between the groups.

**Discussion:** In the current study it can be concluded that abutment shifting from healing abutment to a permanent abutment did not compromise the mucosal attachment since the dimensions and character of the mucosal compartment were comparable and re-attachment was established. In addition, there was no notable change in marginal bone levels, which remained stable once equilibrium was established after exposure. These results are in general agreement with other studies.

The presence of an inflammatory infiltrate in the connective tissue compartment was routine and supports previous findings, however there was a significant increase in the area of the infiltrate for the G2 group which had their healing abutments changed for two-piece hollow prepable abutments. The increased infiltrate may have resulted from handling in the laboratory or due to the increased risk of microleakage that is thought to exist at hollow abutments.

# Peri-implant tissues at submerged and non-submerged titanium implants

**Abrahamsson, I.**
**Berglundh, T.**
**Moon, I.S.**
**Lindhe, J.**

**J Clin Periodontol**
1999;26, 600-607

**Purpose:** To study the hard and soft tissue integration around Astra Tech components when used in a conventional one-stage and two-stage transmucosal surgical technique.

**Material and Methods:** This animal study used the partially edentulated mandibles of 6 beagle dogs. Three months post-extraction, 3 Astra Tech TiOblast™ implants 8 x 3.5 mm were inserted unilaterally, with the most coronal bevel of the implants at the crestal cortical margin. Cover screws were placed and implants submerged for 3 months prior to a second surgical procedure to expose and secure UniAbutments of 1.5 mm and 3.0 mm in length. At the same time a further 3 implants were surgically inserted in the contra-lateral side, with the coronal bevel of the implants once again level with the crestal cortical bone. However for these implants, abutments were placed immediately and soft tissues sutured around them for transmucosal healing. All dogs were routinely followed-up with daily hygiene.

Radiographs were taken using a modified Eggen technique to allow the accurate measurement of mesial and distal bone levels at time of fixture placement, 3 months post insertion and 6 months post insertion. Measurements were made mesially and distally using an imaging system under light microscope.

Clinical examinations were carried out to record plaque scores and a modified gingival index. Animals were sacrificed 9 months after the first implantation procedure and implants were harvested *en bloc* prepared and embedded for ground sections or for the fracture technique to allow histometric analysis of the dimensions and type of hard and soft peri-implant tissues, with particular attention to the *zone of connective tissue integration*. In addition a digital assessment of bone-to-implant contact in both the coronal unthreaded and threaded portions of the implant were undertaken. Results were subject to statistical analysis.

**Results:** Clinically all implants included in the analysis demonstrated successful osseointegration and very low levels of plaque and excellent soft tissue health. Radiographs revealed that over the 9 months follow-up marginal bone loss measured as a mean 0.42 mm for implants subjected to the two-stage technique and 0.3 mm for those treated transmucosally. Histology revealed identical tissue types to be found in relation to the various implant components. Histometric measurements revealed a very close approximation for the two groups with the junctional epithelium measuring as a mean 1.9 mm, the connective tissue compartment measuring 1.17 mm and the distance from the abutment/fixture junction to the marginal bone level measuring 0.8 mm as a mean. With regards the morphometric measurements for the connective tissue zone again there was a very close approximation for all fractions including collagen, vessels, fibroblasts and residual tissues. Bone-to-implant contact for the coronal unthreaded portion measured 75.0% for the one-stage implants and 72.6% for the two-stage implants and 61.4% and 66.7% respectively for the threaded portions.

There was no statistical difference for any parameters measured.

**Discussion:** The notion that an implant can be left exposed at the time of surgical insertion, without impacting on the tissue integration has been questioned and studied with various implants. This study compared the two surgical techniques for the Astra Tech TiOblast™ fixture and UniAbutment. Results clearly indicated that the tissue types, their dimensions and morphometry were identical regardless of procedure and that the percentage of bone-to-implant contact and marginal bone height is also unaffected.

In similar experimental set up differences in radiographic bone loss compared to this result have been reported, in favour for the Astra Tech implant system. Differences most likely explained by the different design characteristics of the implant systems evaluated (i.e. features related to the characteristics and design of the abutment connection).

# The barrier between the keratinized mucosa and the dental implant. An experimental study in the dog

**Moon, I.S.**
**Berglundh, T.**
**Abrahamsson, I.**
**Linder, E.**
**Lindhe, J.**

**J Clin Periodontol**
1999;26, 658-663

**Purpose:** The connective tissue and junctional epithelium constitute the effective barrier between the oral environment and the peri-implant bone. The purpose of the present study was to investigate the tissue composition that forms the transmucosal passage around, and attachment to a dental implant.

**Materials and Methods:** 36 implants (TiOblast™ Astra Tech) were inserted in the healed ridge of 6 dog mandibles and left submerged to osseointegrate for 3 months. Abutments were then connected (UniAbutment™ 45°) and a plaque control program was initiated.

The dogs were euthanized after 6 months by intra-arterial perfusion of a fixative. En bloc specimens were processed for the "fracture technique", and subsequently embedded in EPON. 3 µm thin histological sections were stained with PAS and toluidine blue. In addition ultra thin (0.05 µm) uranyle acetate and lead citrate contrasted sections were also produced.

Light microscopic analysis was performed using a Leica DM-RBE® microscope equipped with an image-capture system (Q-500 MC®; Leica, Germany). The area analyzed was the closest peri-abutment tissue (length 200 µm x 20 µm wide) interposed between the apical border of the junctional epithelium and the bone, called zone A. Continuous with and lateral (or outer) to zone A, zone B was defined (length 200 µm x 160 µm wide).

Determination of the proportions (%) of collagen, fibroblasts, vascular structures and residual tissue (e.g.leucocytes, nerves, matrix components) were analyzed histometrically.

Electron micrographs were obtained from the ultra thin sections revealing the proportion of fibroblasts (using a point counting procedure and a 42-point lattice) in two zones, where one zone (30 µm wide, located within zone A) was innermost next to the implant-abutment surface, and the other zone (30 µm wide, located within zone B) was at a peripheral distance of 150 µm.

The null hypothesis was rejected at $p<0.05$, and the Student t-test for paired observations was applied.

**Result:** The most coronal barrier, the junctional epithelium, was 2 mm long and 40 µm wide. The connective tissue analyzed seemed to be in direct contact with the implant surface. Light microscopic evaluation indicated a structural difference between the innermost and lateral tissues. The innermost tissues (zone A) were characterized by an abundance of fibroblasts (28%) oriented parallel with the implant surface, and interposed by thin collagen fibers (66,47%) which originated from the periosteum of the bone crest running vertically. There was an absence of vascular structures in the inner zone.

The outer zone (B) housed more and larger collagen fibers (82,36%) running in various directions, and a substantial number of vessels (3,27%), but relatively few fibroblasts (10%) were identified. When comparing the inner and outer zones all variables evaluated were found to reach a statistically significant difference, $p < 005$.

**Discussion and conclusion:** The overall result from this study on the composition of the peri-implant connective tissue is in agreement with previously reported data in similar models. Furthermore it confirms that the periimplant tissues are structurally different from gingiva.

A previous hypothesis (from the same group of authors) has speculated that the scar-like barrier tissue composition and the paucity of cells could imply that the peri-implant tissue has a lower turnover than gingiva. In the present study however, a more detailed histological analysis was performed and the previous hypothesis could not be confirmed. To the contrary, there are reasons to assume that the high number of fibroblasts plays a role in the establishment and maintenance of the mucosal barrier and that the tissue next to the implant have a high turnover.

# Three-year evaluation of single tooth implants restored 3 weeks after 1-stage surgery

**Cooper, L.**
**Ellner, S.**
**Moriarty, J.**
**Felton, DA.**
**Paquette, D**
**et al.**

**Int J Oral Maxillofac Implants**
2007;22(5):791-800

**Purpose:** The aim of this 3-year prospective cohort study was to evaluate the outcome of early loading of implants placed in healed maxillary anterior alveolar ridges. Primary variables were implant success rate and prosthesis complications, and secondary variable was to determine the conditions of the peri-implant tissue.

**Materials and methods:** Patients who signed informed consent were included at either of the two centres involved. The recruitment and treatment of the patients were in accordance with Committees for Investigations involving human subjects and the Declaration of Helsinki. Patient inclusion and exclusion criteria has previously been presented in detail (Cooper et al. 2001).

In total, 54 implants (TiOblast™, Astra Tech) were placed in a 1-stage procedure. Healing abutments were connected with light finger pressure. After 3 weeks a definitive abutment was selected, having the restorative margin about 1 mm below the mucosal margin. A temporary crown was cemented and checked for occlusal contacts in maximal intercuspidal position, with limited or no excentric contacts. The placement of the temporary crown was considered the baseline in this study. Eight weeks after implant placement, definitive crown impressions were made and permanent crowns were cemented with glass ionomer cement.

Radiographic and clinical follow-up programme started and was performed at 6 months, 1 and 3 years. Plaque and distance from incisal edge to top of the papilla, and to buccal gingival zenith was measured, as well as the width of the keratinized mucosa. A single independent investigator recorded peri-implant radiolucencies and marginal bone levels in relation to a reference point on the implant.

Descriptive statistics were calculated with a 95% confidence interval. The P value was calculated by Wilcoxon signed rank test.

**Results:** Forty-eight patients were treated with 54 implants placed in the maxillary canine, central or lateral incisor region. Three implants in 3 patients were lost before definitive crown cementation, giving a cumulative implant survival of 94.4%. Thirty-nine patients with 43 implants attended the 3-year follow-up. No abutment screw loosening or fracture occurred, and prosthetic complications included minor incisal porcelain fracture of 3 crowns, loosening of 2 temporary cemented crowns and 2 episodes of soft tissue character. Clinical evaluation showed low levels of plaque accumulation and only 4% of all sites showed peri-implant mucosal redness, at the 3 year control. The parameters evaluating changes in soft tissue health all showed improved results over time. Papilla size positively changed from permanent crown placement through out the study (0.53 mm at 6 m to 0.74 mm at 3 years) and the result was not an effect of the distance between the adjacent tooth and the implant ($P>0.50$, Kruskal-Wallis test). The distance from the incisal edge to the gingival zenith was reduced, indicating a growth of soft tissue at 1 and 3 years (0.34 ±0.94 mm and 0.51±1.42 mm, respectively). The marginal bone levels indicated initial changes from baseline to placement of the definitive crown (0.47 ±0.44 mm, $P< 0.001$) but no further statistically significant changes were recorded during the 1 and 3-year examinations (mean change from baseline to 3 year =0.42±0.59 mm).

**Discussion:** This study showed that early loading of TiOblast™ implants with MicroThread™ is associated with similar level of implant survival (94.4%) compared to single tooth implants of the same type conventionally loaded.

With regards to soft tissue healing and early loading protocols, this study clearly showed on a rapid and predictable reproduction of the peri-implant mucosa. No tissue recession was observed, as previously reported in the literature. The favourable results were attributed to the minimal bone level change, early delivery of well performed provisional restorations and to the stability of the connection of the abutment to the implant (absence of abutment screw loosening).

Minimal and limited marginal bone remodelling was found and there were no abutment related complications. The early loading protocol did not influence the preservation of the marginal bone which is in accordance with previously reported results. Again, the results are an effect of the design features of the Astra Tech implant system, having minute threads on the implant neck, an inner conical connection of the abutment to the implant, and a moderately rough implant surface.

# Incidence of inter-proximal papilla between a tooth and an adjacent immediate implant placed into a fresh extraction socket: 1-year prospective study

**Lops, D.**
**Chiapasco, M.**
**Rossi, A.**
**Bressan, E.**
**Romeo, E.**

**Clin Oral Impl Res**
2008;19(11):1135-40

There have been numerous publications on the immediate placement of single-tooth implants into fresh extraction sockets with the purpose of preserving both the hard and soft tissue framework including the interproximal papillae in order to achieve a good esthetic result. The success of implants placed in this manner has been very high typically > 90% and often > 95%. While some studies have questioned the ability of an implant to prevent bone resorption following extraction, numerous studies have presented data demonstrating maintenance of the interproximal papilla so long as the vertical distance from the crest of bone to the contact point did not exceed 5 mm.

**Purpose:** The current study was set up to assess both the vertical and horizontal distances necessary to ensure maintenance of the interproximal papilla at single-tooth implants.

**Materials and Methods:** Forty-six systemically healthy patients who smoked less than 10 cigarettes per day, demonstrated no evidence of parafunction and were deemed to have a thick or normal biotype were enrolled to the study for replacement of a single tooth using an immediate extraction and insertion protocol, for the placement of an Astra Tech OsseoSpeed™ implant. 32 maxillary and 14 mandibular teeth were atraumatically extracted using luxators and forceps under full flap reflection, after which sockets were thoroughly curetted to remove any residual periodontal remnants. Osteotomies were prepared according to manufacturer's recommendations and the coronal margin of the implants was leveled at the crest labial bone to achieve an appropriate emergence profile. Temporary healing abutments were secured and flaps repositioned and sutured to ensure complete coverage of the residual socket defect. Temporary restorations were fabricated and secured after 8 weeks and definitive ceramo-metal restorations placed 3 months later. 15 restorations were based on customized Cast-Design™ abutments, 21 on prepared Profile Bi-Abutments™ and 10 on zirconia Zir-Design™ abutments. All abutments were secured according to manufacturer's recommendations and either ceramo-metal or all-ceramic crowns cemented on top.

Clinical parameters assessed were gingival index, presence or absence of papilla, where less than or equal to half the papilla fill to the contact point rendered a papilla "absent". The distance from the coronal margin of the implant to the adjacent tooth (dI-T) and the distance of the peak of bone adjacent to the tooth to the contact point (dPBT-CP) were measured on digitalized (and calibrated to the known implant length) radiographs at the 12-months review. Repeat measurements were taken for 10 radiographs to determine intra-observer variability and results were subject to statistical analysis using the $X^2$-test.

**Results:** All implants osseointegrated. A total of 92 interproximal sites were evaluated and the intra-observer variability was negligible. In 97% of sites the gingival index was 0. The mean dI-T for mesial and distal sites was 3.2 mm and 3.1 mm respectively and the mean dPBT-CP measured 5.6 mm for both mesial and distal sites. Using odds ratio it could be demonstrated that when dI-T was 3–4 mm the papilla was present 84% of the time, $p < 0.05$. By contrast when dI-T was < 3 mm it was only present 32% of the time although this was not statistically significant. With respect to dPBT-CP, when the value measured was 3–5 mm the papilla was present 80% of the time, $p < 0.05$, however for measurements of 6–7 mm the papilla was present only 51% of the time (NS).

**Discussion and Conclusions:** It is apparent from the current results that the position of an implant in an apico-coronal as well as a mesio-distal direction is critical to the maintenance of a full interproximal papilla and the accomplishment of an esthetic result. In addition it has been previously reported that immediate implant placement might yield more favorable results in this regard when compared to a delayed approach. As with previous reports this study supports the proposal that the peak of the bone related to the adjacent tooth is more influential than that related to the implant, with the distance dPBT-CP being identified for control of papilla fill.

However this is also dependent on the location of the contact point which should be 5 mm from this bone peak. The Astra Tech OsseoSpeed implant was seen to perform extremely well in the immediate single-tooth replacement scenario.

# Astra Tech single-tooth implants: an audit of patient satisfaction and soft tissue form

**Palmer, R.M.**
**Farkondeh, N.**
**Palmer, P.J.**
**Wilson, R.F.**

**J Clin Periodontol**
2007;34, 633-638

**Purpose:** One area that influences the patient satisfaction scores for implant treatment is the interdental papilla form and the factors that determine its presence, absence or degree of fullness. Different studies have reported differing methodology but in general the results would indicate that implants are less capable of retaining a full papilla compared to natural teeth.

This study set out to determine patient satisfaction levels with single-tooth implants and to compare these scores to a rating by the clinician in light of papilla fill and marginal bone levels, as well as to consider the relationship between the two.

**Materials and Methods:** Sixty-six patients treated for single-tooth replacement in the anterior maxilla were enrolled to the study. All implants had been in function for a minimum of 12 months. Patient questionnaires were completed as part of their recall program with a scale of 1 to 6 to score each parameter from extreme dissatisfaction to total satisfaction. Parameters included crown form and color, masticatory and phonetic function, comfort, and ease of care. In addition, 4-site pocket depths were recorded along with a score for the papilla fill (Jemt index) where 0 = no papilla to 4 = papillary hyperplasia.

Intra-oral radiographs were taken using a Rinn device for standardization. In order to identify contact points (CP), fine orthodontic wire was tightened around each contact to allow accurate measurements of both vertical and horizontal distances taken from the first bone-to-implant contact to the contact point fBIC-CP, the peak of periodontally sound bone adjacent to the natural tooth to the contact point, pBNT-CP, implant shoulder (IS) to fBIC as well as the horizontal distance from the shoulder of the implant to the adjacent tooth, (HD). Results were subject to both paired and two-group t-tests as well as the Mann-Whitney-U test.

**Results:** Sixty-six patients all scored their crowns as a 6 for color and form compared to a score of 4.5 – 5.5 as scored by the clinicians, ($p < 0.001$). With respect to function all patients again scored 6. Twenty crowns were devoid of contact points thereby excluding them from the radiographic analysis, but all these crowns were associated with normal looking papillae. For the other 46 crowns almost 50% of papillae received a score of 2 and 50% received a score of 3 (ideal). No papilla scored 0 or 4. Probing revealed mean pocket depths of 2.63 mm at implants compared to 2.09 mm at teeth, ($p < 0.001$).

Radiographic analysis revealed that the mean of the mesial and distal median distances for fBIC-CP measured 9.3 mm for a papilla score of 2 and 7.7 mm for a papilla score of 3. The average distance for pBNT-CP measured 6.58 mm for a papilla score of 2 and 5.26 mm for a score of 3. HD measured 2.6 mm for a papilla score of 2 and 1.85 mm for a score of 3. The distance IS-fBIC measured 0.0 mm in most circumstances as bone was at the reference level. The differences between values for papillae with a score of 2 and 3 were highly significant on the mesial side only, (tooth $p < 0.001$; implant $p = 0.002$). There was a highly significant difference between distances of IS-CP in favor of the distal surface of implants which gave the impression that radiographic distance for bone levels was better on the distal side.

**Discussion and Conclusion:** The current study provides conclusive evidence that there is a high chance of fulfilling patient's expectations with a single-tooth implant, with patient satisfaction scoring consistently higher than the clinicians. This corroborates previous studies.

With respect to papilla fill as it relates to peak bone levels, previous studies have lacked clarity, with techniques such as bone sounding yielding imprecise data. This study utilized a novel technique for imaging the contact point so that accurate and reproducible measurements could be made radiographically.

These data reveal a similar trend to that already proposed but with slightly different numbers. In the current study a papilla score of 3 (ideal) could be achieved when the critical CP- pBNT distance measured 6 mm for teeth, or when the CP- fBIC measured 8.5 mm for implants, at the 95% confidence interval. These values are greater than those proposed by Tarnow et al, whose 5 mm rule is universally adopted, where some loss of papilla would be expected at 6 mm. In addition no influence was found on the horizontal distance between teeth and implants, with bone being retained at the implant reference level in almost all sites. This may be related to implant design.

The finding that distal values were smaller was significant and this may be due to a more apically located contact point as has previously been proposed. This was confirmed through radiographic measurements of the distance IS – CP, which indicated that the distal CP was typically 1.5 mm more apical than the mesial CP. This may have an impact on papilla form although there was no significant discernable difference between mesial and distal papilla fill in the current study.

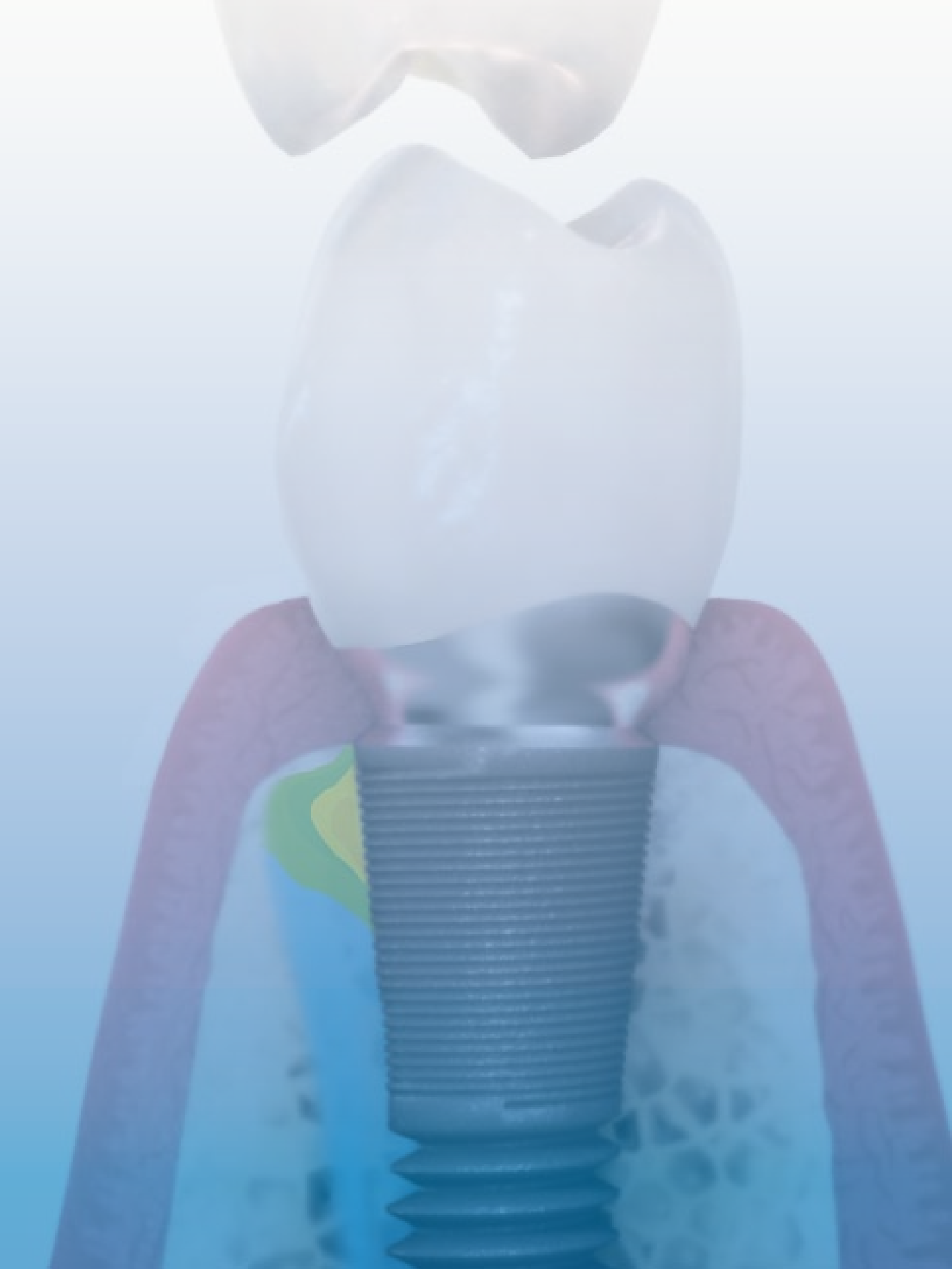

# Immediate/early loading protocol

When high primary stability is achieved, immediate and early loading protocols have been reported safe and successful in the scientific literature.

In this section, you will find summaries on documentation of immediate and early loading using the Astra Tech Implant System™.

## Immediate



*To read more, please see 9, 46, 84*

## Early



*To read more, please see 11, 33, 55, 79*

# Immediate mandibular rehabilitation with endosseous implants: simultaneous extraction, implant placement, and loading

**Cooper, L.F.**
**Rahman, A.**
**Moriarty, J.**
**Chaffee, N.**
**Sacco, D.**

**Int J Oral Maxillofac Implants**
2002;17, 517-525

**Purpose:** This study was established to determine the clinical outcome and implant survival when extracting teeth, placing implants and immediately loading them with either screw-retained or cemented acrylic resin fixed dentures.

**Materials and Methods:** Ten healthy edentulous patients were enrolled in to the study. All patients underwent the initial fabrication of a fully extended upper denture and a short span acrylic denture (second premolar to second premolar), set up on mounted and articulated diagnostic master casts on a semi-adjustable articulator. The mandibular dentures were further amended at time of surgery. Prior to processing an interocclusal record was fabricated to record the relationship between the maxillary and mandibular prostheses.

During surgery patients underwent dental clearance, alveolectomy and implant placement (TiOblast™ 3.4, 4.0) according to manufacturer's protocol and under antibiotic prophylaxis. Extra attention was paid to achieving parallelism to aid prosthesis location. Only implants achieving a good primary fixation were included for immediate loading, otherwise cover screws were placed to allow for submerged healing. For all other implants, modified transmucosal healing abutments were secured into the implants and the mucoperiosteal flaps repositioned and sutured. Modified healing abutments were subsequently used for customization or were replaced by prefabricated screw retaining abutments. Mandibular dentures were hollowed out and located utilizing the distal flanges and the occlusal relation with the new upper denture. The customized abutments or bridge cylinders were captured in the denture using autopolymerizing resin. Dentures were removed, trimmed appropriately and polished before cementation or being secured into place by bridge screws.

Patients were asked to keep to a liquid diet for one week and to use chlorhexidine rinses. Soft diets were required during weeks 2 and 3 postoperatively. After 21 days of healing patients diets were unrestricted. All patients were definitively restored with acrylic/gold screw-retained prostheses after 3 months.

**Results:** A total of 54 implants were placed, of which 48 achieved good primary fixation and were utilized for an immediate loading protocol.

Healing was uncomplicated for all patients and all reported minimal discomfort. At the 3 month appointment all submerged implants which had been exposed and the immediately loaded implants were immobile and there was a 100% baseline survival. Bone levels were seen to remain close to the top of the implant at the implant-to-abutment junction.

The only recorded complications were fracture of the provisional bridge in two patients, debonding of the fixed denture in the same two patients and a fractured acrylic tooth in one patient.

**Discussion:** In the current study an immediate loading protocol was adopted, such that the implants were provisionally restored within hours of placement allowing for an immediate but progressive loading of the implants, controlled by strict instruction regarding diet. Interestingly in the current study no effort was made to over-engineer the cases to provide insurance against implant failures, such that each patient received typically 5 to 6 implants, of which a minimum of 4 were used to support the immediate provisional bridge. This was considered possible in light of previous reports of high success with immediate loading and in recognition of the advantages of using a micro-roughened implant surface, since this is known to aid clot retention, improve primary stability and optimize osseointegration.

The study also demonstrates the efficacy of using a two piece modular implant for a one-stage procedure, thereby allowing abutment changes to accommodate shrinkage of soft tissues prior to fabrication of the definitive prostheses, and submergence of those implants which do not attain good immediate primary fixation.

# A retrospective analysis of peri-implant tissue responses at immediate load/provisionalized microthreaded implants

**De Kok, I.J.**
**Chang, S.S.**
**Moriarty, J.D.**
**Cooper, L.F.**

**Int J Oral Maxillofac Implants**
2006; 21, 405-412

Immediate provisionalization of dental implants placed into fresh extraction sockets, carries with it many possible advantages not least significantly reduced manipulation of the tissues, reduced exchange of transmucosal components and an opportunity to preserve ridge dimension. It has been postulated that such advantages would be translated to a measurable maintenance of the crestal bone levels at the implant with a functionally and esthetically enhanced peri-implant mucosa. Such evidence has been presented for implants which benefit from a conical implant-abutment joint as well as microtexturing and microthreading of the implant.

**Purpose:** This retrospective study was established to assess immediately provisionalized single-tooth implants to evaluate the peri-implant status up to 30 months following insertion.

**Materials and Methods:** Twenty-eight subjects treatment planned for the extraction of one or more teeth were enrolled to the study. Patients were not required to be dentally fit, and local infection or smoking were not considered as exclusion criteria.

Implants were placed at the time of extraction and implant dimensions were matched to the size of the extraction socket and the available bone apical to the socket. Either Direct Abutments or Bi-Abutments were secured to the implants using manual finger torque and provisional crowns were fabricated from resin and cemented with permanent cement. All implant related or abutment related complications were noted and marginal bone levels were assessed relative to a fixed reference point on the implant at x7 magnification.

In 20 patients a clinical examination at 6 and 30 months, allowed assessment of the peri-implant soft tissues in order to measure pocket depth (PPD) at 6 points around each implant and to record bleeding on probing (BOP). Papilla fill was also assessed mesially and distally and scored using the Jemt index.

**Results:** A total of 43 implants were placed as far distally as the premolars. In 3 patients 4 implants became mobile within 6 weeks and were removed and replaced. These patients were excluded from the study leaving 25 patients with 39 implants (12 central incisors, 9 lateral incisors, 5 canines, and 13 premolars).

Mean PPD measured 3.0 mm interproximally and 2.5 mm in the midfacial zone and in general there was an absence of BOP. Marginal bone data revealed a mean bone loss of 0.32 mm mesially and 0.27 mm distally. Only 3 implants were associated with bone loss greater than 1.0 mm with approximately 85% demonstrating bone loss of less than or equal to 0.50 mm. The mean distance from the peak of bone to the contact point measured 4.53 mm mesially and 4.05 mm distally. This limited bone loss was reflected in 95% of all papillae scoring 1 or 2.

**Discussion and Conclusion:** The current study supports previously published data for this particular implant design to confirm that a propitious marginal bone level can be maintained over the long-term. This bone maintenance may be related to a number of factors besides implant design, in particular the use of minimal surgical trauma with an absence of periosteal stripping, the use of a definitive abutment at the time of implant placement thereby avoiding swopping out of abutments, which can disrupt the delicate junctional epithelium, as well as the use of pure titanium or ceramic abutments which have been shown to offer an enhanced soft tissue response. Furthermore depth of implant placement has been shown to affect marginal tissue response with concerns for deep margins leading to tissue irritation exacerbated by deep excess cement which cannot easily be removed.

In the current study the PPD measurements as well as the distances measured from bone to the contact points support the proposals of others that a biologic width exists around implants, which requires a dimension of around 2.5 mm to be established and that in the presence of this dimension a full papilla can exist alongside bone which remains level with the implant-abutment interface. When the various considerations described above are respected it appears possible to obtain a predictable peri-implant health with implants immediately placed and provisionalized after tooth extraction.

# Implant rehabilitation of the atrophic edentulous maxilla including immediate fixed provisional restoration without the use of bone grafting: A review of 1-year outcome data from a long-term prospective clinical trial

**Toljanic, J.**
**Baer, R.**
**Ekstrand, K.**
**Thor, A.**

**Int J Oral Maxillofac Implants**
2009;24(3):518-526

The immediate restoration of implants placed into the edentulous maxilla has received some attention with the literature providing supporting evidence for high success/survival outcomes as measured by implants retained in function over the short-term. However there is still a need for further study in this area particularly for treatment of the atrophic maxilla where low bone volume and density might result in a compromised outcome.

**Purpose:** This study therefore set out to monitor the success/survival of implants placed into atrophic maxillae and subject to immediate restoration as part of a long-term prospective study.

**Materials and Methods:** Twenty-four men and 27 women with atrophic edentulous maxillae scored as C, D or E according to the Lekholm & Zarb classification and with a bone quality scored as either 3 or 4 were consecutively enrolled to the study in two different centers. Selected implant sites had to be capable of receiving at least an 8 mm x 3.5 mm implant without the need for bone grafting. Patients who had uncontrolled disease either locally or systemically or who smoked were excluded as were any patients who had received earlier bone grafting procedures.

All patients were treatment planned to receive 6 OsseoSpeed™ (Astra Tech) implants placed via a conventional approach. The drilling protocol was adjusted to allow for low density bone, resulting in under-preparation where necessary, so the self tapping implants could attain a higher degree of primary stability. When necessary the most distal implants were angulated to avoid any breach into the sinus cavities. Where buccal dehiscences occurred, exposing threads, no action was taken to cover the threads since grafting was not part of the study protocol. Straight or angulated abutments were connected at time of surgery and appropriate copings secured to them prior to repositioning of the flaps for suturing. Screw-retained prostheses were fabricated by either a direct or indirect technique. For the former, the patient's own existing denture was trimmed, hollowed and relined in situ over the copings to allow a direct pick-up. For prostheses fabricated via the indirect route, an abutment level impression was taken and a previously prepared tooth set-up was located to the master cast and processed around the copings. Prostheses were finished according to standard techniques. All prostheses were delivered within 24 hours.

Data on implant dimensions, site location, bone density and volume were all recorded as was primary stability measured by peak insertion torque values (PIT, Ncm). Standardized radiographs were taken using a paralleling device to measure the bone level under x7 magnification and to the nearest 0.1 mm relative to the bevel at the top of the implant. At 12 weeks post-op all restorations were removed to allow the fabrication of the definitive prostheses. At this time implants were individually assessed for osseointegration and radiographs taken. Definitive prostheses were inserted approximately 22 weeks after surgery when another set of radiographs were taken. At 12-months post-op patients were once again recalled for removal of prostheses to allow direct implant assessment and for additional radiographic evaluation.

**Results:** A total of 306 implants were inserted into bone which was relatively evenly classified between categories C & D and between qualities 3 and 4. PIT values ranged from <10 to >45 Ncm (50% 0 – 25 Ncm). 25 patients were provisionalized via the direct method. There was 1 patient drop-out and a total of 12 implants (5 patients) were deemed failures within the 12-week provisional period (4%). At time of definitive prosthesis placement there was a mean bone loss of 0.5 mm +/- 0.7 mm with no additional bone loss noted at the 1-year recall. No single parameter could be identified as being associated with the failures.

**Discussion and Conclusion:** The data from this 1-year interim report would seem to suggest that even implants placed into the atrophic maxilla without the use of any bone grafting can be successfully restored and placed into immediate functional loading, with survival data and marginal bone loss data being comparable to that reported elsewhere. This may present a more appealing treatment strategy to patients with little apparent additional risk.

# A multicenter 12-month evaluation of single-tooth implants restored 3 weeks after 1-stage surgery

**Cooper, L.**
**Felton, D.A.**
**Kugelberg, C.F.**
**Ellner, S.**
**Chaffee, N.**
**Molina, A.L.**
**Moriarty, J.D.**
**Paquette, D.**
**Pamlqvist, U.**

**Int J Oral Maxillofac Implants**
2001;16, 182-192

**Purpose:** This 3-year prospective study set out to document the survival of Astra Tech Fixture ST placed in the anterior maxilla, and subject to a rapid loading protocol.

**Material and Methods:** Patients were recruited when requiring replacement of one or two teeth in the anterior maxilla. All patients presented with bone volume that would allow an implant longer than 11 mm to be placed. Patients were excluded on the grounds of unstable dental disease, parafunction, occlusal instability, smoking or low bone density. A diagnostic work-up with mounted study models and tomographs was completed for each case.

At time of implant surgery a single-tooth implant (Astra Tech, ST) was placed according to manufacturer's protocol to achieve good primary fixation. A healing abutment was then secured using finger pressure so as to effect a transmucosal healing. After a 3-week period, the healing abutment was removed and a final abutment secured, again with finger pressure, to ensure that the restorative margin was 1 mm below the mucosal margin. A direct temporary crown was fabricated at the chairside using Protemp and was cemented with Temp Bond.

A baseline long-cone radiograph was taken, along with an assessment of implant mobility, papilla index, presence or absence of inflammation, presence or absence of plaque, and width of keratinized tissue.

Eight weeks after surgery the temporary crown was removed and a final impression taken for the subsequent fabrication and cementation (glass ionomer) of the definitive ceramic, or ceramometal crown. At this time the abutment screw was tightened to 20 Ncm. Data was collected at 6 months and 1, 2 and 3 years post insertion of the temporary crown. In addition radiographic follow-up allowed the assessment of peri-implant radiolucencies, as well as the marginal bone changes with respect to an established reference point on the implant.

**Results:** 57 implants were placed in 51 patients, however 4 patients were subsequently found to be smoking and were excluded. For the remaining 53 implants, the majority of surgical sites presented with type 2 or 3 bone quality and class A or B bone volume. 70% of implants were longer than 13 mm and 83% were inserted in the central or lateral incisor positions. Of these implants one was diagnosed as a failure at time of temporary crown fabrication and another at 8 weeks, when the master impression was due, yielding a survival rate of 96.2%. At the 1-year recall there was minimal evidence of peri-implant mucosal inflammation (3.6%), with a net gain in papilla length of 0.61 mm.

Radiographic follow-up revealed a 0.59 mm change in marginal bone levels, which appeared to stabilize after 9 weeks, with 70% recording a bone loss of less than 1 mm. No complications were recorded with respect to abutment screw loosening. Some prosthetic complications were recorded with respect to crown de-cementation and crown fracture. One case of peri-implant mucositis recovered uneventfully, when treated with antibiotics.

**Discussion and Conclusion:** A survival rate of 96.2% is comparable with other single-tooth studies utilizing a standard protocol for unloaded healing. In addition tissue response was favorable, with a healthy maintenance of marginal bone and filling out of interdental papillae, aiding a good esthetic result. Implant design and the conical implant-abutment connection have been cited as important factors in the maintenance of these tissues, and also contribute to a stable connection, highlighted by an absence of abutment screw loosening.

In conclusion this study demonstrates that in the presence of good primary stability, single-tooth implants can be subject to a rapid loading protocol, yielding an efficacious and predictable result.

# A retrospective analysis of early and delayed loading of full-arch mandibular prostheses using three different implant systems: Clinical results with up to 5 years of loading

**Eliasson, A.**
**Blomqvist, F.**
**Wennerberg, A.**
**Johansson, A.**

**Clin Impl Dent Rel Res**
2009;11(2):134-148

**Purpose:** The current study was established to identify any differences that might exist between delayed and early loading with respect to implant success, hard and soft tissue response as well as prosthodontic complications over a 5-year period. In addition the study was designed to reflect a cross-sectional representation of clinical circumstances where different clinicians with differing expertise were using different implant systems.

**Materials and Methods:** 109 patients treated by one of 10 teams, each comprising a different surgeon and restorative dentist received fixed screw-retained mandibular bridgework, 55 with early loading and 54 with delayed loading. Subjects were retrospectively included in the study and their assignment to either the delayed (DL) or early loading (EL) group was according to the presence or absence of medical history in particular irradiation, diabetes, heavy smoking (> 20/day) or bruxing habit. As such this assignment was non randomized. 47 patients wore a full upper denture.

All patients received 4 to 6 implants in the mandible with those in the DL group benefitting from submerged healing. In the DL group patients received Mk III Brånemark implants with either a machined or TiUnite® surface (BM, BTU) or Astra Tech TiOblast™ implants (AT). In addition in the one stage EL group some patients received Straumann® SLA implants (SLA). In the EL group prostheses were delivered within 2 weeks of surgery, while in the DL group prostheses were delivered after 3 months and the framework were either milled titanium (Procera) or cast gold. The patients in the EL group were instructed to stick to a soft diet for the first month.

All implants were radiographed at 3 months post surgery (baseline) and at 1 and 5 years. Changes in marginal bone levels (ΔMBLC) were assessed at x7 magnification. All clinical parameters related to peri-implant health were assessed and a note recorded of any adverse events related to the prostheses or soft tissues. The space between the prosthesis and soft tissues was measured by evaluating the thickness of impression material placed into the gaps at the central incisor, canine and second premolar positions to the nearest 0.1 mm. If prostheses were removed for any reason individual implant mobility was assessed. All prostheses were assessed for passive fit. Results were subject to statistical analysis.

**Results:** 26 Patients were lost to follow up. A total of 378 implants in 83 patients were available for analysis. In the EL group12 implants failed (4.8%), 6 BTU, 5 BM failed within the first year and 1 AT failed after the 5 years. In the DL group 5 implants failed prior to loading (2.1%), 3 were BM and 2 were BTU. After 5 years follow-up mean ΔMBLC from baseline measured -0.93 mm in the EL group and -0.53 mm in the DL group. Throughout the study over 50% of implants lost no bone in either group, however Brånemark implants with a conical collar lost significantly more bone in the EL group (-4.20 mm), $p < 0.01$, most of which was lost at baseline. AT implants lost the least amount of bone over 5 years with a mean ΔMBLC of +0.15 mm in the EL group and -0.10 mm in the DL group. ΔMBLC for specific implants did not vary statistically between loading protocols.

Few soft tissue complications were noted with only 3 patients being diagnosed with peri-implantitis. All were restored with Brånemark implant of both surface types. Soft tissue shrinkage was more evident in the EL group but was not significant. In both groups more shrinkage was noted anteriorly, approximately 1.0 mm.

Prosthesis survival was 92.5% in the EL group and 98% in the DL group. A variety of adverse events were recorded from veneer fracture to framework fracture in one case. Problems were notably more frequent in the EL group and statistically more common in the maxilla, $p < 0.05$.

On questioning, significantly more patients were satisfied in the EL group compared to the DL group, ($p < 0.05$).

**Discussion and Conclusion:** In general it was clear that while some differences exist between the frequency of complications, and maintenance between EL and DL groups which was clinically significant ($p < 0.05$), clinical success could be achieved with early loading, with a 92.5% prosthetic survival rate and a 94.4% implant survival rate. Some system specific differences in tissue response, notably maintenance of marginal bone was evident especially for the conical BM implants which lost significantly more bone than any of the others, while the AT implants consistently demonstrated the smallest mean marginal bone level change. Nonetheless all systems were seen to perform equally well with comparable survival rates over 5 years in function.

# Outcomes of a fluoride modified implant one year after loading in the posterior-maxilla when placed with the osteotome surgical technique

**Stanford, C.**
**Johnson, G.**
**Fakhry, A.**
**Gartton, D.**
**Mellonig, J.**
**Wagner, W.**

**Appl Osseointegration Res**
2006;5, 50-55

**Purpose:** This study was established to evaluate the clinical outcome of a fluoride modified (OsseoSpeed™) implant used for the restoration of the posterior maxilla, where bone density is known to be low, utilizing an osteotome technique for bone condensation and sinus floor tenting where appropriate.

**Materials and Methods:** This report presents outcome data from the first 20 consecutive patients recruited to a prospective study of 45 patients in total. Patients received 2 or 3 OsseoSpeed implants per quadrant placed at least 7 mm apart and with 1 mm of bone circumscribing the implants. One stage surgery was applied and no open sinus lifts were performed.

Initial osteotomy preparation was via graded drills at 1500 r.p.m. and an assessment was made of bone density. Final osteotomy preparation was via osteotomes whose dimensions were specific to implant geometry. At this time any sinus floor elevation was undertaken for elevation of the Schneiderian membrane and grafting was employed at the surgeon's discretion, but only with autogenous bone. Any dehiscence or fenestration type defects were also grafted with autogenous bone and covered with a collagen membrane.

Unloaded healing took place for 6 weeks at which time the implants were restored with a provisional restoration. An assessment of stability was made using resonance frequency analysis (RFA) at 2 weeks post-operatively. Subsequent to loading, RFA measurements were taken again along with clinical assessment of mobility, plaque, bleeding and probing depth. Standardized radiographs were also taken to assess mesial and distal marginal bone at 6 weeks post loading and then again at 3, 6 and 12 months to determine changes in the level with respect to a reference point at the top of the implant. Definitive restorations were placed one year after loading.

**Results:** Seven males and 13 females comprised the group, with a mean age of 59 years. A total of 59 implants were placed of which 56% were in low density type 4 bone and the remainder were in types 2 or 3 bone. 34 implants were associated with an indirect sinus lift procedure and grafting with autogenous bone. For these implants, the mean bone height to the sinus floor measured 6.5 mm. 51% of implants were 11 mm in length and 27% were shorter than 10 mm. The majority were of a tapered design being 4.5 mm diameter at the crest.

Six implants were mobile at the 6 week evaluation and were therefore not loaded at this time. Another 6 implants were noted to lack primary stability and benefited from a delayed loading protocol, i.e. mean of 13.8 weeks. An additional 10 implants also had delayed healing but this was a deviation from protocol rather than out of necessity. Of the 12 implants that had mobility one was removed due to pain at 6 weeks.

When considering changes in implant stability over time the RFA revealed little change over the first year of loading for the pooled implant data. However, when grouped by bone quality there was a highly significant difference between types 2 and 4, ($p < 0.001$), with a significant effect of time, ($p = 0.02$).

No significant difference in crestal bone loss were found for placement with different techniques.

Indeed implants in types 3 and 4 bone showed no bone loss in 80% and 85% of sites respectively.

**Discussion and Conclusions:** Stability values were seen to increase significantly over time when implants were judged to have been placed in types 3 and 4 bone. Such changes were not apparent for type 2 bone. Marginal bone changes were similar to those reported with studies in which only a drilling protocol was used, suggesting that a comparable outcome is possible when using osteotome compression technique.

When considering the unstable implants all but one appeared to attain stability with time, and these remained integrated up to the endof the one year follow-up.

It can be concluded that the use of fluoride modified implants placed in the posterior maxilla using an osteotome technique achieve an acceptable clinical outcome even when subject to an early (6 weeks) loading protocol.

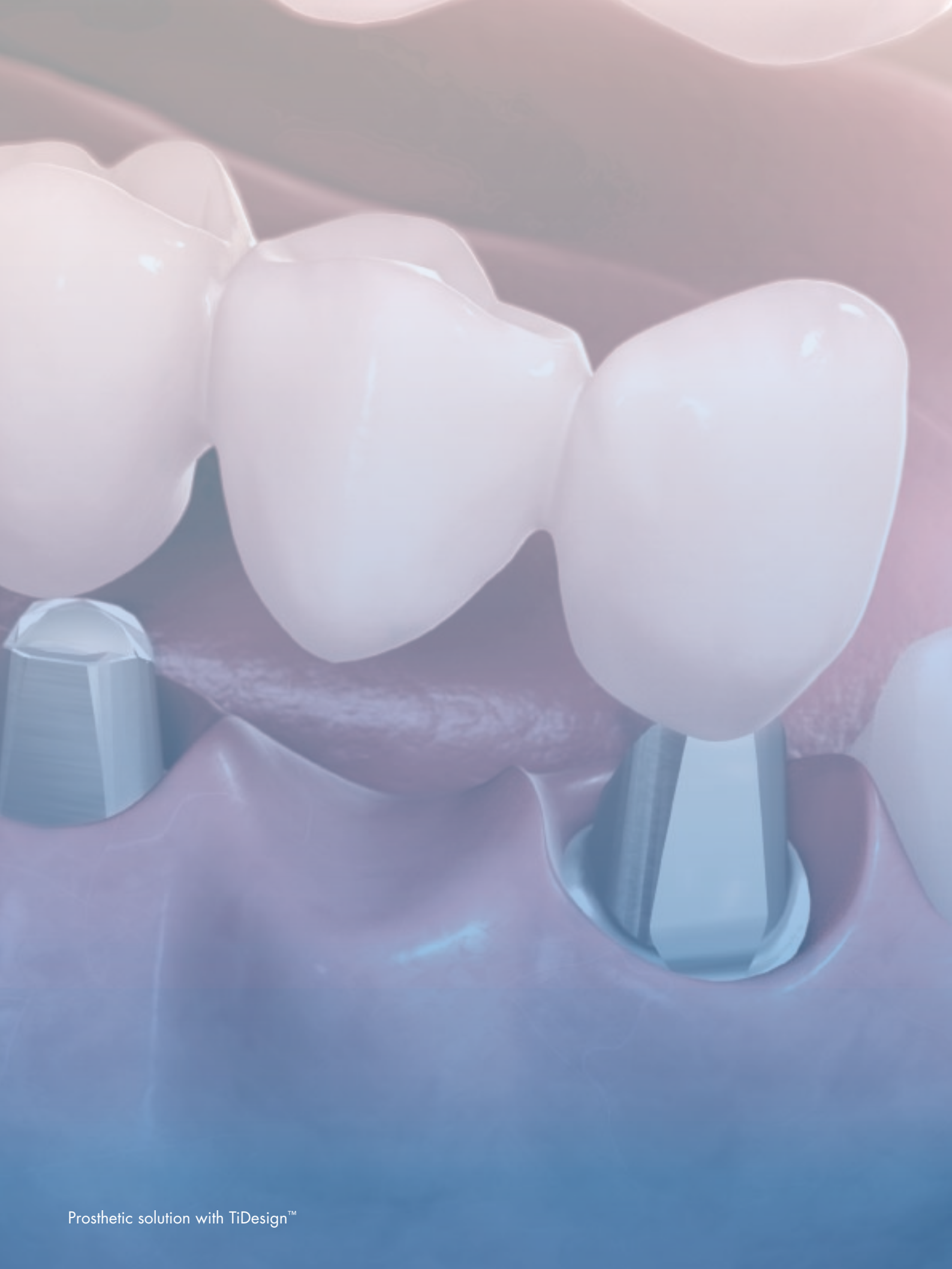

Prosthetic solution with TiDesign™

# Prosthetic solutions

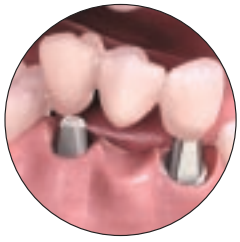

The Astra Tech Implant System™ has been documented when used to support a wide range of prosthetic solutions. Good clinical and mechanical results have been obtained for single tooth, fixed partial and complete prostheses as well as for removable overdentures. Please read more about it in this section.

## Single tooth



*To read more, please see 33, 64, 67*

## Fixed partial or complete prostheses



*To read more, please see 18, 63, 68*

## Overdentures



*To read more, please see 10, 69*

# A short-term clinical evaluation of immediately restored maxillary TiOblast single-tooth implants

**Norton, M.**

**Int J Oral Maxillofac Implants**
2004;19:274-281

**Purpose:** The purpose of this study was to evaluate the short-term clinical outcome of single tooth Astra Tech implants placed in the maxilla and immediately restored with cementless friction-fit temporary crowns using the Abutment ST and the ST impression coping/healing cap.

**Material and Methods:** Thirty-three patients consecutively treatment planned for replacement of single missing units were enrolled to the study. Patients either presented with a failing natural tooth or with an already healed extraction site. Patients were required to be systemically healthy and smokers were included.

For patients with failing teeth, these were atraumatically extracted using the periotome, and osteotomy sites were prepared per socket. The point of entry for these osteotomies was in the most palato-apical position to avoid fenestration of the delicate labial plate. For healed sites a scalloped palatocrestal incision was utilized with minimal flap reflection. Osteotomy preparation essentially followed manufacturer's recommendations, except for use of the conical drill which was either abandoned or only used against the palatal shelf of bone in larger extraction sockets. It was a requirement that implants (Astra Tech ST 4.5) achieved a primary rotational stability of 25 Ncm otherwise they were excluded from the study.

An abutment ST 0.0 mm was routinely used and the abutment screw torqued to 25 Ncm. An ST impression coping was then adjusted into a cap and used as a core for the fabrication of a chairside temporary crown. This was typically achieved by grinding a matching denture tooth down to a veneer and bonding it to the cap with autopolymerizing methylmethacrylate. This technique presented the advantage that the temporary crowns could be left friction fit, without the need to initially use cement in a fresh surgical site. The crown was kept clear of centric and excursive contacts. Subsequent regular removal of the temporary crown after one month of healing allowed for direct submucosal irrigation with chlorhexidine to maintain healthy soft tissues. All patients were followed up regularly until the time of definitive restoration placement which was typically of an all-ceramic type.

Baseline radiographs were taken using a Rinn device. Patients were reviewed at 6 months, one year and annually thereafter. The most recent radiograph was used to evaluate marginal bone changes relative to a fixed reference point on the implant at the level of the fixture/abutment junction.

**Results:** Eight patients were excluded due to inadequate primary rotational stability of their implants. For the remaining 25 patients, 28 implants were available for evaluation. Only one implant failed due to a perceptible mobility one month after surgery. The remaining 96.4% continued to survive under occlusal load for up to 30 months in function with a mean marginal bone loss of only 0.4 mm, with 37.5% recording no marginal bone loss at all with respect to the reference level.

Indeed a number of implants demonstrated bone above the implant/abutment junction. Loosening or failure of the temporary crowns occurred in 39% of cases necessitating their cementation or re-fabrication. It is clear that early cementation would significantly reduce this complication.

**Discussion:** The current study supports the use of the Astra Tech implant system for the immediate temporization of implants to replace failed or missing teeth. The high survival and excellent marginal bone data would indicate that the design of this implant yields a favourable peri-implant tissue response between marginal bone and the implant/abutment junction. The mean distance between these levels was only 0.4 mm suggesting that favourable soft tissue esthetics can be achieved. The use of a friction-fit temporary crown offered a simple and esthetic solution to temporisation. However the use of a small amount of temporary cement could help reduce incidence of crown loosening and/or fracture.

# Implant-supported single-tooth restorations: A 5-year prospective study

**Wennström, J.L.**
**Ekestubbe, A.**
**Gröndahl, K.**
**Karlsson, S.**
**Lindhe, J.**

**J Clin Periodontol**
2005;32, 567-574

**Purpose:** This prospective study set out to evaluate the 5-year clinical and radiographic outcome of implant supported single-tooth crowns.

**Materials and Methods:** Forty-five Astra Tech ST implants (MicroThread™ design on the implant neck) were inserted into forty healthy patients requiring one or more single-tooth implants. A lack of bone volume necessitating augmentation excluded a patient from the study. However if dehiscences occurred during implant preparation, these implants were included but no efforts were made to cover the dehiscence defects. Smokers were included (n = 12). All implants benefited from a two-stage protocol according to standard surgical techniques. 89% of implants (n = 40) were inserted into the maxilla. At exposure, a prefabricated ST abutment was connected to ensure that the abutment shoulder was 1–2 mm below the mucosal margin and an acrylic temporary crown was fabricated chairside. On completion of the treatment all patients received a ceramometal crown, which was cemented with zinc phosphate cement.

Patients were followed up for 5 years to record the clinical parameters including plaque score, mucositis, and pocket probing depth and radiographic outcome with particular emphasis on monitoring the marginal bone changes. Radiographs were taken at crown insertion (baseline) and annually thereafter. Measurements were made by two independent radiographers at x7 magnification to determine the distance between the implant reference point, at the top of the implant and the first point of bone-to-implant contact. Marginal bone data was statistically analyzed at both the patient level and implant level.

**Results:** Only one implant was known to have failed after 2.5 years of function. However 4 implants were lost to follow-up due to death or patient relocation, however of these two were confirmed to be retained in function without complication by telephone interview. Thus the overall implant survival rate was 97.4%. One abutment screw loosened in two patients, one after one year and the other after 4.5 years. In a third patient the abutment screw loosened twice before the implant eventually failed. This patient was diagnosed as a bruxer.

In the first year of function marginal bone loss measured 0.02 mm and 0.11 mm at the end of the study period. 24.5% implants appeared to demonstrate an improved bone height after 5 years of function compared to baseline. These changes were not significant. Interestingly there was no significant difference between smokers and non-smokers.

Clinical parameters were stable, with low plaque and bleeding scores and the majority of pockets measuring <3 mm.

**Discussion and Conclusion:** In the current study only minimal changes were seen to the marginal bone levels around free-standing Astra Tech ST implants. Implant survival was 97.4% and compares favourably with other studies. There was a 6.5% technical complication rate due to abutment screw loosening (3/45).

Marginal bone changes were minimal and compared very favourably to existing data where a greater initial bone loss is seen after exposure to baseline, typically 1.5 mm. No such bone loss was seen at the Astra Tech ST implant with a marginal bone loss of only 0.06 mm from baseline to the first year recall. This is remarkable when one considers that approximately one third of the implants were associated with a dehiscence type defects, which have been shown to result in interproximal bone loss if left untreated.

# Bone level changes at axial- and non-axial-positioned implants supporting fixed partial dentures. A 5-year retrospective longitudinal study

**Koutouzis, T.**
**Wennström, J.**

**Clin Oral Impl Res**
2007;18(5):585-590

**Purpose:** The knowledge about the influence of tilted or angulated load conditions on implant success and marginal bone reactions are spare. The aim of this retrospective study, involving periodontally compromised patients, was to evaluate the potential influence of implant angulation on the marginal bone level. Freestanding implant supported fixed partial dentures were followed for a 5 year period.

**Materials and methods:** The analysis was performed based on 38 patients rehabilitated with 42 fixed partial dentures supported by totally 111 Astra Tech implants (TiOblast™). Conventional loading was applied and the fixed prosthesis were connected approximately 4 weeks after abutment connection. The majority of the screw retained FPDs were connected to 3 implants (n=27) while a minority were supported by 2 implants (n=15). Approximately half of the FPDs had a cantilever extension.

Measurements of the implant inclination were made from standardized photographs (identical projection) of the master casts. Photos were taken both with the cast in occlusion and with guide pins abutment pick-up in place. The photographs were then superimposed in a computer program. For each implant the inclination in a mesial-distal direction in relation to a vertical axis perpendicular to the occlusal plane was measured with a protractor on the computerized photos. In cases with only 2 implants, buccal-lingual assessments were performed from photographs taken in the transversal plane. Methodological error as well as interexaminer reproducibility were addressed in a random selection of 5 cases. The mean difference was only 0.15° and 0.07°, respectively.

Independent radiologists unaware of the purpose of the study evaluated the marginal bone levels from radiographs taken with the standardized parallel long cone technique and custom made stents. Comparisons were made between baseline (prosthetic delivery) and the 5 year follow up. The inter individual difference between the two radiologists revealed a neglectable difference (0.04 ±0.33 mm).

The Mann-Whitney U-test was applied for comparison of the bone level changes between axial and non-axial loaded implants. Spearman correlation analysis was carried out on FPD level for the analysis of inter-implant inclination and the 5-year bone level changes.

**Result:** The tail quartile of the implants defined as axial positioned showed a mean angulation of 2.4º. The non-axial implants had a mean angle of 17.1º. Thus, the implants were moderately tilted (<30º). The mean marginal bone loss after 5 years of functional loading was 0.4 mm (SD ±0.97) and 0.5 mm (SD ±0.95) for the axial and non axial positioned implants, respectively. Thirty-nine and 37% of the axial and non-axial positioned implants showed no bone loss at all, after 5 years in function. There was no statistically significant difference between axial and non-axial loaded implants on marginal bone loss.

**Discussion:** The study revealed no difference in marginal bone loss between axial or non-axial loaded implants after 5 years of loading. One important factor for this result may be the high level of oral hygiene control, preventing biofilm formation and inflammatory lesions. Studies have previously reported on other risk factors for increased marginal bone loss, for example smoking, jaw of treatment and implant and abutment lengths, however correlation to those characteristics was not performed in this study. The study did not show any increased incidence of technical complications associated with tilted implants.

# A prospective 3-year study of fixed bridges linking Astra Tech ST Implants to natural teeth

**Palmer, R.M.**
**Howe, L.C.**
**Palmer, P.J.**

**Clin Oral Impl Res**
2005;16: 302-307

**Purpose:** The purpose of this study was to evaluate the clinical and radiographic outcome of both teeth and implants used to provide combined support for 3-unit fixed partial dentures.

**Materials and Methods:** Twenty-one patients were recruited for the restoration of free-end saddles using the most distal natural abutment and an implant placed distal to that. All natural abutments were periodontally healthy.

In 13 cases the implant was placed such that there was a middle pontic but in 6 cases the pontic was cantilevered distally and the implant was placed directly adjacent to the natural abutment.

A total of 21 Astra Tech ST 4.5 mm implants were placed according to a conventional protocol and were either 9 mm (n = 2), 11 mm (n = 11) or 13 mm (n = 8) in length. Subsequent to abutment connection impressions were taken with the natural abutment prepared to accommodate a gold telescopic coping. An implant-head impression was also captured so that the technician could prepare a Profile BiAbutment parallel to the telescopic coping on the natural tooth. A composite-gold suprastructure was then fabricated on a master model of the copings in situ and these were secured with temporary cement.

Follow-up radiographs were taken using customised holders for the paralleling technique and standardization. In addition plaque scores, bleeding on probing and probing depths were recorded.

Radiographs were evaluated by an independent examiner at x7 magnification, to the nearest 0.1 mm. Marginal bone levels were measured with respect to the reference point at the top of the implant and the crown margin on the natural tooth. Tooth intrusion was also measured. Results were subject to statistical analysis.

**Results:** Two patients were lost to the study each with a middle pontic design and the results are therefore expressed for the remaining 19 patients.

There were no implant failures and all prostheses remained in functional occlusion. Plaque scores increased from baseline, $p < 0.02$ however this was not reflected in changes for bleeding on probing. Probing depths also increased from baseline, $p < 0.001$.

With respect to marginal bone levels the 3 year data revealed an increase in bone loss of only 0.13 mm at the implants and 0.39 mm at the natural teeth. These changes were not statistically significant. The frequency of no bone loss at implants was 53% and at teeth was 42%.

The commonest complication was bridge decementation (42%) and in one site a loose abutment screw was detected. Composite fracture or chipping was also recorded for 8 bridges, necessitating repair. No tooth intrusion was noted.

**Discussion and Conclusion:** In this prospective study it was possible to demonstrate the efficacy of connecting an Astra Tech ST implant to a single healthy natural abutment to support either a cantilever or mid-pontic 3-unit fixed partial denture. Implants and teeth remained immobile, with insignificant changes in the marginal bone levels. There was no evidence of tooth intrusion. Prosthetic complications were mainly restricted to decementation, which was addressed by using a mid-strength cement and composite fracture, which necessitated occlusal refinements and repair. The technique helped to avoid additional sinus graft procedures.

# Bone level change at implant-supported fixed partial dentures with and without cantilever extension after 5 years in function

**Wennström, J.**
**Zurdo, J.**
**Karlsson, S.**
**Ekestubbe, A.**
**Gröndahl, K.**
**Lindhe, J.**

**J Clin Periodontol**
2004;31, 1077-1083

**Purpose:** This retrospective study set out to analyze the effect of cantilevers on marginal bone levels at implants supporting freestanding fixed partial dentures (FPDs).

**Materials and Methods:** Fifty-one periodontally compromised patients were restored with a total of 56 FPDs supported by Astra Tech implants. All patients had undergone a comprehensive periodontal program before, during and after implant reconstruction. Of the total series 6 FPDs had less than 5 years follow-up, 3 FPDs were in patients lost to follow-up and a further 3 FPDs failed as a result of implant failure two of which had cantilever units. Thus 50 FPDs were available for radiographic analysis. Of these 24 had cantilever extensions (Group C) and 26 did not (Group NC). All FPDs were screw-retained and a classic healing and two-stage surgical protocol was employed. The two groups were comparable for age, number of remaining teeth, prevalence for smoking, and number of supporting implants which was 2.6 as a mean for the cantilever group and 2.8 for the non-cantilever group. For group C, 16 FPDs were maxillary and 8 were mandibular compared to 12 and 14 respectively for group NC. The mean number of units per FPD was 4 for group C and 3 for group NC.

Cantilevers were on average 9.0 mm long. Three cantilevers were kept clear of the occlusion. Radiographs of each implant were obtained using standardized long cone radiographs in customized film holders. Baseline radiographs taken at prosthesis insertion were compared to those taken at the 5-year follow-up. Bone levels were recorded with respect to the implant-abutment junction. Marginal bone levels were analyzed at the FPD level, the implant level or the surface level (i.e. the distal surface of the most distal implant related to the cantilever or absence thereof.)

Statistics was performed by the use of a bivariate analysis (Mann-Whitney U-test) and a stepwise regression analysis utilized to evaluate influence of confounding factors on the longitudinal peri-implant bone level change.

**Results:** For the pooled data the mean marginal bone loss (xMBL) measured 0.4 mm. The xMBL for maxillary FPDs measured 0.6 mm compared to 0.2 mm for the mandible, ($p < 0.05$). The xMBL for implants in group C measured 0.49 mm compared to 0.38 mm in group NC. The bone loss at the most distal surface of the distal implant in both groups measured 0.35 mm and 0.22 mm respectively. 33% of the implants in group C recorded a bone loss of >1.0 mm compared to only 19% in the NC group. None of the above results demonstrated any significant difference.

When stepwise regression analysis was used, the only factors that appeared to influence longitudinal bone changes was smoking and treated jaw.

**Discussion and Conclusion:** In this retrospective cohort study with a 5-year follow up, the inclusion of a distal cantilever did not appear to negatively influence marginal bone loss data whether considered at the FPD level, the implant level or more importantly at the level of the implant surface facing a cantilever. However data did reveal a tendency towards small increases in marginal bone loss for implants supporting cantilever prostheses. This might be a reflection of the fact that a greater proportion of FPDs in group C were maxillary and as such may not have been a reflection of the presence of a cantilever at all. The only other related influential factors on longitudinal bone levels was smoking and treated jaw. The overall mean peri-implant bone level change over 5-years in function was 0.4 mm, which is by all standards very small. Only 6 technical complications were recorded, equally distributed between the two groups.

In conclusion, the findings in the present study show that inclusion of cantilever extensions in patients with good oral hygiene and well performed occlusion (of the prosthesis) may not jeopardize the long-term prognosis of the Astra Tech implant supported FPDs.

# Clinical and radiographic outcomes of implants immediately placed in fresh extraction sockets

**Gökçen-Röhlig, B.**
**Merçi, U.**
**Keskin, H.**

**Oral surg Oral Med Oral Pathol Oral Radio Endod**
2010;109(4):1-7

**Purpose:** The objective of this study was to evaluate the 2-year clinical and radiographical outcome of implants; supporting a mandibular overdenture and placed in fresh extraction sockets or in healed ridges.

**Materials and Methods:** Ten consecutive patients visiting the Faculty of Dentistry, University of Istanbul, were included in the study. All patients had been treatment planned to receive a maxillary complete denture and an implant supported mandibular overdenture on the day of extraction of failing mandibular teeth. Exclusion criteria were general contraindications for implant surgery, previously grafted bone or implant failure, poor plaque control and clinical attachment loss of 4 mm or more on the buccal aspect of the tooth to be extracted.

Each patient received 4 OsseoSpeed™ implants (position 34-44); 2 immediately placed in extraction sockets and 2 placed in healed ridges, using an open flap surgery and local anaesthesia. The gap between the implant and socket wall was augmented by locally harvested bone. Sutures were removed after 1 week. The permanent overdenture was attached by locators after 4 months of healing. Recalls were performed at 3, 6, 12 and 24 months post loading and osseointegration was considered successful if the criteria according to Buser et al. 1990 were met, i.e. no peri-implant infection, pain, foreign body sensation, dysaesthesia, radiolucency around the implant or implant mobility. Modified plaque index, modified bleeding index and probing pocket depth were recorded at 4 sites of each implant. Mobility of the prosthesis, width of the keratinized mucosa and any adverse event reported by the patient were also recorded. Radiographic evaluation of the marginal bone was done at the 1- and 2-year visits, and were compared to baseline (prosthetic loading). Intra-oral radiographs were taken using the long-cone parallel technique and marginal bone levels assessed at mesial and distal sites.

Descriptive statistics were calculated, and the chi-square test was used to detect statistically significant differences between the two groups (i.e. $p < 0.05$).

**Results:** Implant survival and success rate were both 100%, and no discomfort or pain were recorded during the course of the study. Clinical parameters were similar in the two groups and did not change over time. Bleeding and plaque indexes equals to 0 in slightly more than 80% of the sites, and less than 15% of the sites scored 1. Bone level changes were on average 0.58 mm (SD±0.42) and 0.72 mm (SD±0.45) after 1 year in function for healed versus extraction sites. Additional remodelling occurred to the same extent in the two groups during the second year in function, (mean 0.59 mm and 0.64 mm for healed and extraction sites). Hence, changes in the marginal bone were slightly higher in the extraction group. One screw loosening and 2 fractured resin teeth were reported.

**Discussion and conclusion:** Out of 40 implants placed none were lost or failed. There were no differences between implants placed in extraction sockets and healed ridges as measured by clinical parameters. Marginal bone level changes met the success criteria defined for implant treatment proposed by the 1st European Workshop on periodontology (1994). No major prosthetic complications occurred. The successful results presented here can be explained by a careful preoperative evaluation and the grafting method.

In conclusion, provided a careful patient selections is done, immediate placement is a safe, reliable and less time-consuming treatment alternative for patients in need of tooth extraction before implant treatment.

# Surgical techniques

A wide range of different surgical techniques are applied when placing implants under different preconditions. The summaries below show that one- and two-stage surgery, immediate placement in extraction sockets, bone augmentation and sinus lift can be successfully and predictably performed using the Astra Tech Implant System™.

## Immediate placement/extraction sockets



*To read more, please see 34, 38, 39, 51, 79*

## Bone augmentation



## Sinus lift

# A prospective, randomized-controlled clinical trial to evaluate bone preservation using implants with different geometry placed into extraction sockets in the maxilla

**Sanz, M.**
**Cecchinato, D.**
**Ferrus, J.**
**Pjetursson, E.**
**Lang, N.**
**Lindhe, J.**

**Clin Oral Impl Res**
2010;21(1):13-21

Immediate placement of dental implants into extraction sockets has been demonstrated clinically and histologically to be as predictable as implant placement in healed sites. The immediate placement of dental implants in extraction sockets is associated with residual bone defects between the walls of the extraction socket and the neck of the implant at the time of placement. Depending on the size of this defect, various studies have recommended the use of regenerative materials or barrier membranes to fill or cover these gaps thus preventing epithelial or connective tissue cell ingress, favoring bone regeneration. While some studies can demonstrate that immediate placement in an extraction socket may prevent or decrease the hard tissue loss which predictably follows tooth loss, others have shown that as new bone is formed around the implant, corresponding bone loss from the buccal and lingual aspects of the ridge can be demonstrated.

**Purpose:** The aim of this prospective, randomized, controlled multi centre study was to determine the association between the size of the void established using two different implant configurations and the amount of buccal/palatal bone loss occurring during healing following implant installation into extraction sockets.

**Material and Methods:** Ninety-three patients (≥18 years) requiring the extraction of a maxillary tooth in the 15 to 25 region fulfilled strict inclusion criteria for this study. Following the atraumatic extraction of the tooth using a periotome, patients were randomly allocated to group A or B. Group A utilized uniformly cylindrical implants whereas group B utilized implants which were cylindrical in the apical aspect but tapered cervically. All implants (MicroThread™ OsseoSpeed™ Astra Tech AB, Sweden) were placed with healing abutments according to the manufacturer's protocol. In order to evaluate the bone at time of placement and to describe the size of any defects between the socket walls and the implant surface, the following landmarks were defined: Implant surface (IS), Implant Rim (IR), Top of bone crest (BC), Inner border of bone crest 1 mm from BC (IBC), Outer border of bone crest 1 mm from BC (OBC) and base of the defect (DB). After placement, the following measurements were taken, by independent examiners, on the buccal and palatal aspects of each implant, to the nearest millimeter using a standard periodontal probe: IS-IBC (Horizontal defect), IS-OBC (Horizontal distance from implant to outer crest of ridge), IR-DB (Vertical Defect), IR-BC (vertical distance from implant rim to bone crest). The buccal and palatal bone wall thickness was measured with calipers. A strict postoperative regime followed, with review after 1 week. Implants were allowed to heal for 16 weeks prior to re-entry to repeat the previous measurements prior to restoration.

The results were subjected to statistical analysis at the 95% confidence interval to test the null hypothesis that the reduction in the buccal bone plate thickness is constant, irrespective of the size of the void established by using different implant geometries,

**Results:** The mean reductions in IS-OBC, and IR-DB were not significantly different between the two groups on either the buccal or palatal aspects. Similarly, whilst there was no difference between the groups in reduction of IR-BC, the reduction was seen to be more pronounced at the buccal aspect. The measurement IS-IBC showed a significantly greater amount of reduction in group A than in group B on both the buccal and palatal aspects, $p < 0.05$.

**Discussion and Conclusions:** This study reinforces and corroborates the findings of numerous previous studies which have demonstrated that following tooth removal, the bucco-lingual ridge dimension decreases and buccal vertical crest reductions are seen to occur as a result of tooth loss. This marked decrease can be seen to occur regardless of immediate implant placement, the geometry of the implant, or a flapless surgery protocol. Whilst the ridge reductions measured in this study were fairly substantial, it must be considered that additional changes may in fact occur during the later phases of remodeling. This, together with the marked decrease in the vertical crest especially on the buccal aspect, reinforces the importance of proper planning prior to implant placement and positioning, especially in the esthetic zone to ensure that ridge alterations do not compromise the esthetic outcome of the case.

# Immediate provisionalization of single extraction-site implants in the esthetic zone: A clinical evaluation

**Valentini, P.**
**Abensur, D.**
**Alberini, J.**
**Rocchesani, M.**

**Int J Periodont Rest Dent**
2010;30(1):41-51

**Purpose:** Demands continue to increase for a reduction in healing times and improvements in esthetic outcome for implant supported restorations. To this end much has been reported on the use of immediate loading protocols as well as the placement of implants directly into fresh extraction sockets, with or without the use of regenerative materials depending on the size of the residual socket defect and/or the presence of a dehiscence-type defect. This study was established to monitor success of immediate implants with immediate temporization by virtue of implant survival, maintenance of marginal bone levels and the maintenance of the interdental papilla.

**Materials and Methods:** Data on implants placed in 90 patients were evaluated. Implants were required to be non-adjacent, placed into fresh extraction sockets and had to achieve a minimum insertion torque of > 40 Ncm to qualify for immediate temporization in order to guarantee adequate primary stability. Presence of local infection was an exclusion criterion although if the infection remitted within one week of extraction under antibiotic therapy implants were then inserted into the still fresh socket. Molar sites were excluded from the study. According to the need for grafting, the time of implant placement (day of extraction or one week later) and the time of provisional prosthesis delivery (which varied from the day of surgery up to 14 days post-op) four groups were established.

Surgical approach varied according to the defect type and the need for augmentation. But in general all teeth were extracted atraumatically and buccal flaps were raised, including adjacent papillae to gain direct access to sockets and associated defects. Osteotomies were located towards the palatal and implants (Astra Tech, TiOblast™) were typically located with their shoulder 3 mm below the free gingival margin or 2 mm below the adjacent cemento-enamel junction. When implants were due to be immediately temporized, abutment connection was facilitated and these abutments were definitive and not removed again. Grafting was achieved using bovine bone mineral (BioOss) and when indicated covered with a collagen membrane (BioGide). Temporary crowns were fabricated from shells relined over white plastic prefabricated copings. When temporization was delayed a fixture pick-up was used to register the implant position for location in a study cast and laboratory made temporary crowns were then available for insertion 1 to 2 weeks post-op. Healing abutments were located, flaps repositioned and wounds sutured.

All temporary crowns were kept clear of contacts in centric and lateral/protrusive excursions. Intra-oral radiographs were taken at baseline (day of temporization), and one year after delivery of the definitive crown which was delivered typically 3 months post-op. Cumulative Implant survival (CIS), and changes in marginal bone level (MBL) were recorded.

**Results:** A total of 36 implants were included in the analysis and ranged from 9 to 13 mm in length and 4.0 to 5.0 mm in diameter. Implants were in full function for an average of 2.8 years (range 1–4.1 years). Two implants were removed within 2 weeks post-op. Both these implants were associated with a dehiscence-type defect. The CIS after one year was 95.3%. There were no late failures. MBL measured 0.18 mm mesially and 0.43 mm distally. There were no significant differences between the groups. Visually 78% of implants were associated with complete papilla preservation.

**Discussion and Conclusion:** This study supports other previous studies in that it corroborates the efficacy and success of this technique. However this study is the first to report on combining the immediate placement with local grafting of dehiscence-type defects. It is worthy of note that the two early failures were both associated with such defects and a history of infection. Nonetheless the study suggests that such cases can in general also be associated with a successful outcome, with excellent maintenance of MBLs, which are typically known to exist with this brand of implant. This in turn was seen to help support a full interproximal papilla in 78% of cases and even some hyperplasia in a further 6% of cases. It can be concluded that while the presence of local infection might jeopardize success, the need for local grafting does not appear to inhibit outcome for immediately placed implants.

# Maxillary osteotomy with an interpositional bone graft and implants for reconstruction of the severely resorbed maxilla: a clinical report

**Kahnberg, K.E.**
**Vannas-Löfqvist, L.**

**Int J Oral Maxillofac Implants**
2005;20(6):938-945

**Purpose:** Different surgical techniques in combination with implant therapy have been employed in order to rehabilitate athrophic maxillae. Applying the Le Fort I osteotomy technique allows for the adjustment of the maxilla in both horizontal and vertical directions. The aim of this study was to report on the prospective 5-year data when interpositional bone graft and implants were used for the reconstruction of the extremely resorbed maxilla.

**Materials and methods:** A 2-stage implant rehabilitation procedure was applied. The included patients (15 women and 7 men; mean age 65.7 years) had extreme resorption of the maxilla. Radiographic examination was thoroughly carried out prior to surgery, immediately after the bone grafting procedure, after implant placement, at abutment connection, 1-year postoperatively and then annually for 5 years. Classification of the alveolar anatomy was performed according to modified Cawood and Howell classes. Possible pathological changes of the maxillary sinuses, the borders of the bone grafting area, and marginal bone height with reference to a reference point, were evaluated.

**Surgical procedure:** All patients were treated with an orthognathic surgical procedure using a maxillary osteotomy technique under general anaesthesia. The maxillary bone was cut with an oscillating saw and separated from the nasal bones before down fracture. Meanwhile, both cortical and cancellous bone grafts were taken from the iliac crest to restore the sinus cavities, nasal floor and cavities between the cortical grafts. The grafts were immobilized with osteosutures (stainless steel wires) before repositioning (anteriorly and inferiorly when necessary) with contoured plates to the midface.

Additional analgesics, cortical steroids and antibiotics were given postoperatively. Healing of the bone graft took 4 to 5 months. At the second surgery the bone plates, screws and osteosutures were removed and 8 implants (TiOblast™ ST) with cover screws were inserted. A relined denture was allowed during healing phases, but chewing was not recommended. The patients were restored with a temporary prosthetics solution for the first 6 months. Thereafter fixed permanent gold/acrylic resin restorations were fabricated.

**Result:** All 22 patients attended the 1-year control, 18 patients visited the 2-year follow-up and 50% of the patients were followed for 5-years. Healing after surgery was complication free in most instances.

Three patients developed symptoms of sinusitis.

Loose graft material (which was removed at exploratory surgery) was discovered in two of these patients, obliterated drainage from the sinus in one patient. All patients recovered fully after antibiotic admission.

The mean available bone height before therapy was about 3 mm. Corrections in the sagittal plane were in mean 5.6 mm and in vertical direction 4.7 mm. Evaluations revealed a postoperative bone height of about 14 mm, which was maintained until implant surgery. Between abutment connection and the 5-year examination approximately 1 mm was further resorbed resulting in a general bone height of 12 mm (anterior and posterior regions).

6 implants of 176 failed, all before permanent prosthetic rehabilitation (CSR 97%). In the patients followed for three years (14) or more, no further marginal bone level changes was seen.

**Discussion:** This patient series, many of them previously considered as hopeless cases, clearly show that a cumulative implant survival of 97% is achievable using an orthognathic surgical technique with inlay grafting. These results are similarly good compared to conventional implant treatment in the maxilla. Further, by using moderately rough implant surfaces it was possible to increase the survival and success rates from 85% to 97%, as compared with the use of machined surface implants in similar surgical situations. Small remodelling in the graft material and maintained marginal bone levels were noted throughout the study period.

# Reconstruction of the severely resorbed maxilla with autogenous bone, platelet-rich plasma, and implants: 1-year results of a controlled prospective 5-year study

**Thor, A.**
**Wannfors, K.**
**Sennerby, L.**
**Rasmusson, L.**

**Clin Impl Dent Rel Res**
2005;7(4):209-220

**Purpose:** The primary outcome variable in this controlled clinical study was to evaluate the effect on osseointegration of implants placed after bone grafting with or without adjunctive platelet rich plasma (PRP). A second aim was to compare implant osseointegration of block grafts without PRP with PRP-treated particulated bone.

**Materials and methods:** A split-mouth design was applied in this study. In each patient, the anterior maxilla was divided into test and control sides. Both sides of the posterior maxilla were also divided in test and control. The 19 patients (2 men and 19 women, mean age 58 years), referred to the Maxcillofacial Unit (Stockholm, Söder Hospital) were consecutively included in the study. Inclusion criteria were: signed informed consent; no general medial contraindications for surgery/general anesthesia; no alcohol abuse; cigarette consumption <9 cigarettes per day; residual bone height of 2-5 mm and width < 2mm at planned implant sites, and an age between 20 to 75 years.

A corticocancellous bone graft was taken from the iliac crest under general anaesthesia. The bone was subdivided for placement of onlay block graft (anterior right side), onlay particulated bone graf with PRP (anterior left side), and for inlay grafting with particulated bone with (left sinus) or without (right sinus) PRP. The preparation of PRP was carried out from the patients venous blood (450 mL) by several steps of separation. The PRP was blended with mixture of autologous thrombin and anticoagulated PRP and left to form a gel that could be used together with the bone.

Eight implants were placed in each patient (TiOblast 3.5, n=152, lengths between 9–17 mm) and were left submerged to heal for 6 months when healing abutments were connected. All patients received fixed prosthetic restorations and the 1-year examination was performed after 1-year of loading.

Recording of the marginal bone levels were performed using a picture analysis system (NIH Image) on carefully taken radiographs at prosthetic delivery and after 1-year of loading. The top of the cervical section of the implant neck served as the reference point.

Stability measurements by means of Resonance Frequency Analysis (RFA, Ostell apparatus, giving the value in Implant Stability Quotient, ISQ) was performed at implant installation, abutment connection and after 1-year of loading.

**Result:** Following grafting procedure, two patients developed localized infections that resolved with drainage and antibiotics. A marked resorption of the grafts was generally seen at implant placement. At abutment connection 2 implants were found mobile, giving a total survival rate of 98.7%. Following abutment connection, 4 patients showed penetrations of the cover screws, which also were accompanied by some marginal bone resorption.

The mean marginal bone levels at all test sides changed from 1.3 mm (SD±1.9) to 1,8 mm (SD±1.1) between prosthetic insertion (baseline) and 1-year. The corresponding figures for bone levels on the control side were 1.5 mm (SD±1.7) at baseline to 2.0 mm (SD±0.9) at 1-year follow up. The difference between the test and control was not statistically significant.

The RFA measurements revealed similar stability at implant placement for all implants, but significantly better stability at test sites (PRP) at abutment connection and at the 1-year follow-up, compared to control sites.

**Discussion and conclusion:** The present study could not show any significant differences in clinical outcome when particulated or block grafts were enhanced with PRP or not. An advantage with particulated bone is that it is easier to mold to the contour of the recipient bone. It has further been hypothesised that particulated bone could be more quickly incorporated due to the immediate access of angiogenic and osteogenic cells in the space between the particles of the graft. However, the result could not prove any such advantages. The result did prove on the possibility to achieve predictable clinical result with particulted onlay grafts. Stability measurements revealed significantly better stability for grafted sites augmented with PRP at abutment connection and after 1 year of loading. The reason for this is attributed to the type of graft rather than to an effect of PRP. The level of stability, around 60 ISQ after 1-year, corresponds well to results, reported from other clinical studies.

In conclusion, the results here show on high implant survival and stable marginal bone conditions 1 year after loading in autogenous bone grafted maxillaes. The addition of PRP to the graft had no significant influence on the result, but the use of the rough TiOblast implant may have positively influenced the clinical outcome, compared to if a smooth or machined implant surface had been used.

# Local sinus lift for single-tooth implant. I. Clinical and radiographic follow-up

**Kahnberg, KE.**
**Wallström, M.**
**Rasmusson, L.**

**Clin Impl Dent Rel Res**
E-pub, DOI : 10.1111/j.1708-8208.2009.00201.x

Frequently patients seeking implant reconstruction to replace missing maxillary premolar and molar dentition require sinus augmentation to overcome problems related to inadequate bone height to the floor of the sinus. Typically this involves a large lateral window access for elevation of the Schneiderian membrane and grafting of the extra-sinusoidal space. For replacement of single missing premolars and molars such large access is neither necessary or practical.

**Purpose:** To present a local sinus elevation technique with autogenous bone in a 1-stage approach. And to present radiographic volume changes in the grafted area after 2 years.

**Materials and Methods:** Seven premolars and 11 molars requiring replacement in 20 systemically healthy patients, who reported no history of sinusitis, were undertaken using a local sinus lift. Standardized intra-oral radiographs were taken pre-operatively to confirm a bone height of >2 mm< 5 mm to the floor of the sinus.

Recipient sites were exposed through reflection of a full mucoperiosteal flap to allow a small circular window to be prepared over the sinus for access to elevate the Schneiderian membrane. At the same time an osteotomy was prepared through the crest of the ridge using a standard protocol for the insertion of a single Astra Tech OsseoSpeed™ 4.5 or 5.0 mm Ø implant. Implants were 13 mm to 17 mm in length and acted as a tent pole for the membrane. Bone was collected during lateral window and osteotomy preparation using a disposable Bone Trap™ (Astra Tech) and this bone used to pack into the extra-sinusoidal space around the apex of the implants. A cover screw was placed and flaps repositioned and sutured for primary closure and submerged healing. Implants were exposed after 6 months and subsequently restored using conventional crown therapy. Follow-up radiographs were taken at exposure, and at 1- and 2-years post-op. Radiographs were digitized through image capture and evaluated using a picture analysis system to determine the total vertical bone height (VBHT) at each implant irrespective of the relation of the crest of bone to the implant.

**Results:** There was a 100% survival of all implants at the 2-year review. The mean baseline VBHT was 5.8 + 1.3 mm. Immediately after bone grafting and implant insertion the VBHT measured 13.0 + 1.8 mm. At the 1-year review VBHT measured 11.4 + 3.6 mm, while after 1.5 years of functional loading (2 years post-op) the VBHT measured 10.6 + 2.1 mm giving a net loss of mean loss of VBH of 3 mm over the 2-year period. The mean marginal bone level relative to the implant reference point was -0.83 + 0.77 mm suggesting the majority of change in VBHT occurred at the apical level within the graft. The changes in VBH were statistically significant from baseline to 1-year as well as from the 1- to 2-year follow-up, $p < 0.01$.

**Discussion and Conclusions:** The use of single-tooth implants is today considered the more conservative approach to tooth replacement when adjacent teeth are free of restorations. Unfortunately in the posterior maxilla placement is often made fraught by a pneumatized sinus limiting the available bone height. Historically for multiple implants the lateral window approach for sinus elevation and grafting has been employed while internal sinus tenting has also been presented in the literature, although this technique is more difficult to control with respect to preventing rupture of the membrane.

In the current study a localized lateral window-type technique is described at the same time as osteotomy preparation and implant placement. The need for implants longer than 13 mm remains open to debate and further research but for the purpose of the current study longer implants were utilized necessitating as much as 7-8 mm gain of vertical bone height. This was achieved by using bone collected at the time of surgery using a disposable Bone Trap™, which proved most effective in the collection of the bone debris. Nonetheless the volume of bone was not enough to completely fill the space under the tented membrane and it is proposed that this space has the potential to form new bone de novo under the elevated membrane. In this respect it was observed that when steep sinus walls exist close to the site of the implant, both elevation and tenting of the membrane as well as bone filling was more predictable. The loss of bone height was seen to occur around the apex and is likely due to sinus pressure bearing down on the graft. This might support the use of longer implants, which have been shown to give rise to higher survival rates in sinus grafted sites.

# Bone formation at the maxillary sinus floor following simultaneous elevation of the mucosal lining and implant installation without graft material

**Thor, A.**
**Sennerby, L.**
**Hirsch, JM.**
**Rasmusson, L.**

**J Oral Maxillofac Surg**
2007;65(Suppl 1):64-72

**Purpose:** Traditional sinus lifting techniques have previously been accompanied with various graft materials, however, recent studies indicate that the mere lifting of the sinus membrane in combination with implant placement result in new bone formation. This study aimed to evaluate the bone formation after sinus mucosal lining and simultaneous placement of implants without the use of any graft material.

**Materials and methods:** Consecutive patient inclusion was performed, and 11 women and 9 men (20 patients, mean age 59 years) fulfilled the criteria of having ≤5 mm subantral bone, and were thus treated with the modified sinus lift method. The surgical treatment started in November 2001 and ended in June 2004, at the University hospital Uppsala, Sweden.

Preoperative sedation (when required) and antibiotics were administered prior to surgery which was performed under local anaesthesia. After a mucoperiosteal flap opening, a rectangular osteotomy was made 5–6 mm cranial to the intended implant site in the maxillary sinus wall. An angulation of the bone cut was made to simplify the repositioning of the bony window. The bony window was carefully dissected, removed and kept in a sterile saline compress. The sinus lift was accomplished in all directions from the entrance window prior to placement of longest possible implants (9–15 mm, totally 44 Astra Tech ST implants). In order to allow for adequate clot formation around the implants in the sinus, cooling with saline at placement was not performed. In some cases, the drilling procedure was modified by means of the final drilling step. The conical burr was levelled in to the bone 1–2 mm less than recommended, giving a better primary stability using the effect of the conical neck design and the MicroThread™. The establishment of a sufficient blood clot was checked before repositioning the window and suturing of the soft tissue. The patients were given analgesics and antibiotics postoperatively. Additionally, the patients were instructed to use nasal spray saline for 14 days, not to blow their noses, and not to wear the dentures for 7–10 days.

Prosthetic rehabilitation, primarily single crowns, but also a few cases with full arch bridges, was performed by the referring dentist after a mean healing period of 6 months.

Periapical radiographs and orthopantomograms were used for the evaluation of the bone gain around the implants. Necessary adjustments for axial projections were made using the 5.5 mm high MicroThread area as reference.

**Result:** Perforations of the sinus mucosa at surgery occurred in 11 of the 27 sinus lifts performed. The three largest perforations were sutured while the remaining 8 were so small that further dissection and "tenting" by the implant together with the formation of a blood clot was considered satisfactory. Healing was uneventful in all patients and no infection was observed. Five patients received 1-stage surgery.

One patient lost 1 implant (of 2 inserted) just after abutment placement. No further failures were recorded during the entire follow-up period ranging between 14 and 45 months (mean 27.5 months).

Radiographic evaluation showed a mean gain in bone height of 6.5 mm (SD=2.49 n=44) and a stable marginal bone situation. Two 4.5 mm wide implants in two patients showed a "push out" effect observed already after 3 months. However, the implants remained stable elevated about 2 mm from the marginal bone, throughout the 2 years of follow-up. The regression analysis revealed that longer implants and minimal residual bone resulted in the greatest gain of bone.

**Discussion:** The approach to restore patients with very thin residual alveolar heights with implants without the addition of graft material have many advantages. No additional graft material is needed, thereby reducing the costs and morbidity possibly associated with harvesting of bone grafts. The technique allows for direct installation of implants avoiding long healing times, which is often the case with grafting techniques. Instead, the new bone is formed simultaneously with the osseointegration process. The TiOblast surface may have properties enhancing the local thrombin and coagulation cascade within the clot (compared to machined titanium) resulting in enhanced revascularization and osseointegration.

In conclusion, the maxillary sinus mucosal lining elevation technique shows an implant survival rate of 97.7%, which is well within accepted survival criteria. Furthermore, the method has profound health-economic advantages including shortened treatment times. As a consequence, the performance of sinus lift with grafting technique has decreased significantly at the mentioned University hospital.

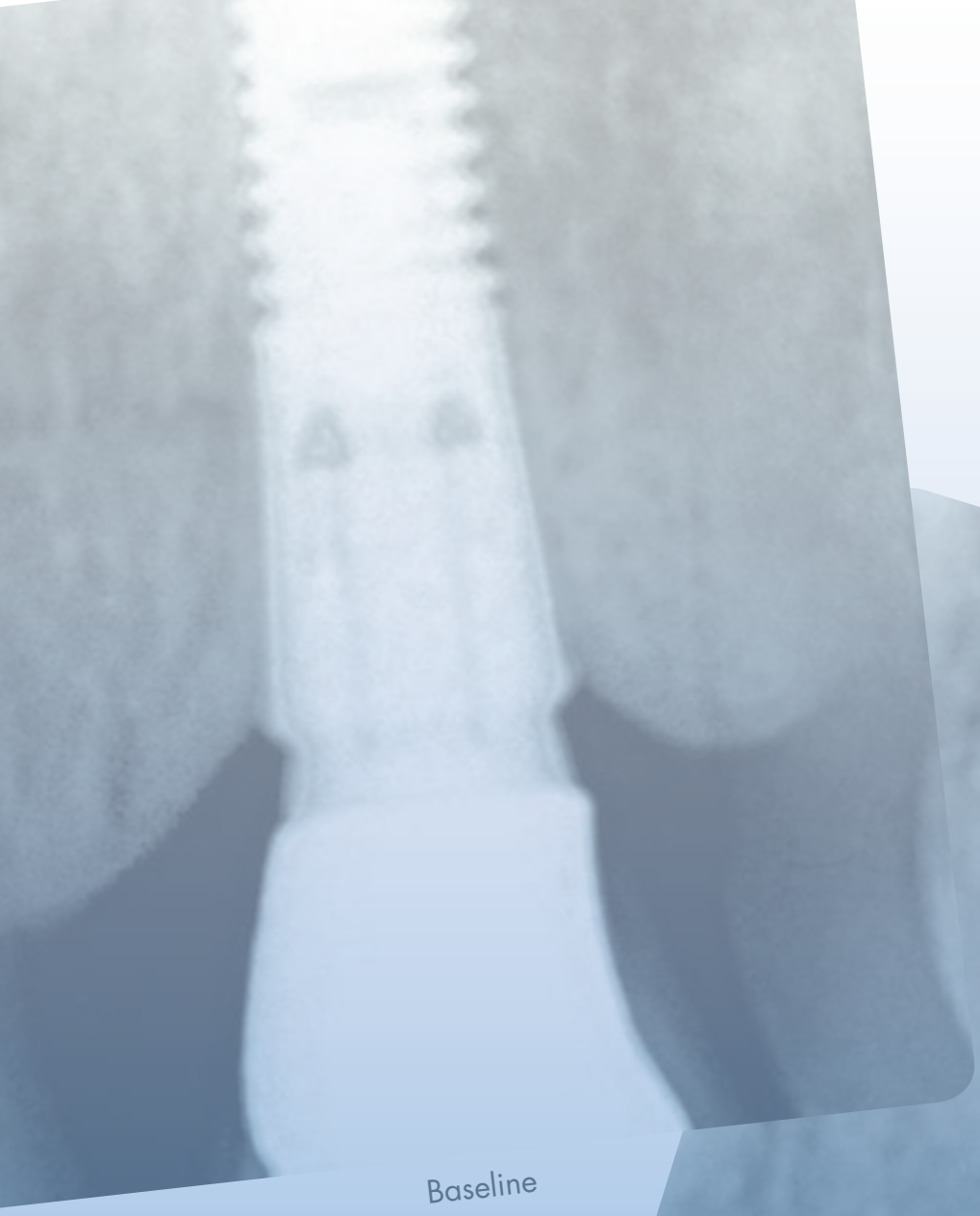

Baseline

Five years follow-up

# Long-term marginal bone maintenance

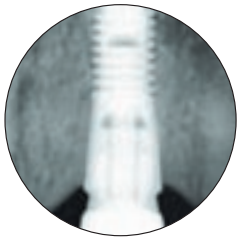

The Astra Tech Implant System™ is designed and proven clinically to maintain marginal bone. Outstanding long-term (i.e. ≥ 5 years) clinical results on the maintenance and preservation of the marginal bone is summarized here. Some of the articles even report on marginal bone gain around Astra Tech implants in several patients.



*To read more, please see 42, 48, 50, 56*

# Longitudinal changes in tooth/single-implant relationship and bone topography: An 8-year retrospective analysis

**Chang, M.**
**Wennström, J.**

**Clin Impl Dent Rel Res**
e-pub DOI
10.1111/j.1708-8208.2010.00272.x

It has been established that the bone peak at the surface of a natural tooth is the dominant factor for determining the fullness of the interproximal papilla between a tooth and an adjacent implant. Furthermore the changes over time in the vertical discrepancy between tooth and implant due to alveolar growth and vertical tooth drift or indeed due to marginal bone loss at the surface of the implant, results in loss of bone height at the surface of the tooth and eventually a loss of papilla height, compromising esthetics.

**Purpose:** This study was established to determine any longitudinal changes in the bone topography adjacent to Astra Tech ST (Single-Tooth) implants.

**Materials and Methods:** Only 4.5 mm diameter tapered implants (TiOblast™, MicroThread™) placed in the upper jaw between 15 and 25 and in function for at least 5 years were included in the study. Baseline radiographs were required from time of crown cementation and then at 5 years follow-up. If 8-year radiographs were available these were also included. All implants were placed using a submerged protocol and allowed to heal for 6 months prior to abutment connection using the ST-Abutment system. At exposure all implants were temporized and definitive crowns inserted one month later. Standardized radiographs were taken using individually fabricated film holders to ensure the film was perpendicular to the x-ray beam. Linear measurements were recorded on digitized images of each radiograph, using the implant diameter and micro-threaded conical collar length to calibrate each radiograph. The most coronal bone contact at the mesial and distal of each implant (CBC) was evaluated with respect to the base of the bevel at the shoulder of the implant, which was used as the reference, 0.3 mm below the microgap. In addition the level of the bone peak at the adjacent teeth was measured from the cement-enamel junction (TBP).

The tooth-implant vertical discrepancy (TIVD) was measured from the cement-enamel junction to the reference line and the horizontal gap (TIHG) was measure from implant surface to tooth surface at the level of the reference line. Apical position was measured in relation to the thread level on the implant.

Measurement error was evaluated using 10 randomly selected images which were re-assessed after a 2 week period. Differences for CBC, and TBP were only 0.01 mm while TIHG was 0.02 mm and TIVD was 0.04 mm. The differences equated to less than half a thread. Results are expressed as mean values, mm (+/- SD).

**Results:** A total of 33 implants were included in the study, 10 of which were in central incisor positions, 9 lateral incisors, and 11 first bicuspids and 3 second bicuspids. The mean change in CBC to 5 years was -0.1(1.1), and for TBP was 0.0 (0.4). 8-year values were -0.1 (1.3) and -0.1 (0.5) respectively. The mean TIVD was 4.1 mm and mean TIHG was 2.1 mm. When assessing the tooth apexl relation to the threads of the implants it was apparent that the vertical change at 5 years measured 0.37 mm for incisors and 0.19 mm for premolars. At 8 years these values were 0.53 mm and 0.15 mm respectively. Statistical analysis revealed no significant influence of any variable on the outcome data. Change in vertical position of adjacent teeth at 5 and 8 years was statistically significant, $p < 0.05$. This correlated to a greater presence of infra-occlusion in the incisor positions, $p = .025$.

**Discussion and Conclusion:** Consistent with previous studies the Astra Tech ST implant demonstrates minimal changes in marginal bone levels, only -0.1 mm over 8 years. Indeed 48% of implants revealed no marginal bone loss, with only 13% demonstrating bone loss > 1.0 mm. Similarly bone loss at adjacent teeth over 8 years was also minimal and it could be confirmed that both vertical and horizontal relationships between tooth and implant exerted no influence over outcome. This finding bodes well for long-term esthetic stability for interdental papillae and gingival zenith for teeth adjacent to Astra Tech ST implants. However ongoing tooth eruption may result in infra-occlusion and a discrepancy of gingival zenith for single-tooth implant restorations.

# Bone level alterations at implants placed in the posterior segments of the dentition: outcome of submerged/non-submerged healing. A 5-year multicenter, randomized, controlled clinical trial

**Cecchinato, D.**
**Bengazi, F.**
**Blasi, G.**
**Botticelli, D.**
**Cardarelli, I.**
**Guadini, F.**

**Clin Oral Impl Res**
2008;19(4):429-431

**Purpose:** This study set out to evaluate the long-term marginal bone level changes at implants placed using a one- or two-stage surgical protocol.

**Materials and Methods:** Eighty-four healthy patients were randomly assigned to either a one-stage (group A) or two-stage (group B) surgical protocol for the insertion of 324 Astra Tech (TiOblast™ 3.5, 4.0) implants to support Fixed Partial Dentures, FPDs. As an inclusion criteria, patients had to present with an adequate amount of bone to receive implants of at least 9 mm in length without recourse to grafting. In the current cohort 25% of the patients were smokers.

Implants were placed according to manufacturer's protocol. For implants in group A, standard UniAbutments were connected at the same operative procedure as implant placement and were left exposed to the oral cavity during the healing phase. For implants in group B, cover screws were placed and the implants were submerged for a healing period of 3 months in the mandible and 6 months in the maxilla. At this time all submerged implants were exposed in a conventional manner and UniAbutments were connected.

The restorative treatment followed recommended protocol for the fabrication of screw-retained FPDs. At definitive prosthesis connection, baseline records were taken for plaque score, mucositis, and intraoral radiographs were taken for bone level measurements. The same follow-up data was recorded at yearly visits during the 5 years course of the study.

Results were statistically analyzed.

**Results:** Four implants in group A and 3 in group B failed to integrate (early failures), 5 of these implants were recorded as having a reduced primary stability. Another 3 implants were lost during the first year (2 fractured and 1 was removed due to advanced bone loss). At the 5-year follow-up, 35 implants were lost to follow-up. Among these, 3 patients (11 implants) had died during the course of the study. In total, 10 bridge screws fractured (5 patients), and 8 veneers had to be replaced (5 patients).

Plaque and mucositis scores were low throughout the study.

Radiographic measurements revealed a mean marginal bone loss of only 0.02 mm for group A implants and 0.17 mm for group B implant after 1 year in function with no significant differences between the groups. After another 4 years in function there was some mean radiographic bone gain in group A (0.07 ± 0.5 mm), and a slight bone reduction in group B (0.02 ± 0.6 mm), but these were not statistically significant from each other. Only 16 implants (4 in group A and 12 in group B) experienced bone loss > 2 mm during the study period.

**Discussion and Conclusion:** The current study was conducted as a randomized controlled study to determine the influence of one- versus two-stage surgical protocol on the long-term marginal bone response. Clinical and radiographic outcome variables indicate that the use of a one-stage surgical protocol did not impact upon the implant success rate, peri-implant soft tissue health, or the change in marginal bone levels which were very minor. Neither did the treatment modality affect the number of technical complications.

# A 10-year prospective study of single tooth implants placed in the anterior maxilla

**Gotfredsen, K.**

**Clin Impl Dent Rel Res**
E-pub Aug 6, 2009,
DOI: 10.1111/j.1708-8208.2009.00231.x

In an effort to achieve a high degree of esthetics and function the single-tooth implant replacement (STIR) has been identified as the treatment of choice, especially when the adjacent teeth are un-restored. The 5- to 10-year survival has been shown to be comparable to that for fixed conventional bridgework, although there are few 10-year follow-up studies on STIR to date. The literature suggests that such studies might demonstrate a higher complication rate. In addition differing protocols for immediate, versus early and delayed placement might yield differing outcomes.

**Purpose:** The aim of this study was to presents 10-year data from a cohort of STIRs placed in both an early and delayed manner and reflect on both biological and mechanical outcome.

Material and Methods: Twenty healthy patients, mean age 33 years, required replacement of a single missing tooth in the anterior segment. Two groups each with 10 patients were assigned to early placement (Group EP) 4 weeks after extraction and delayed placement (Group DP) 12 weeks after extraction. No socket preservation procedures were undertaken. Implants (Astra Tech ST, 4.5 mm ø) were placed with the shoulder bevel leveled with the lingual crest. Any residual buccal defects were protected by a non-resorbable membrane to aid guided bone regeneration. Submerged healing was allowed for 6 months prior to exposure and membrane removal. Implants in group EP were restored using prefabricated abutments while those in the DP group received prepable abutments. All implants were restored with cemented ceramometal crowns. Occlusion was refined to within 40 µm.

Baseline clinical and radiographic assessments were made within 2 weeks of crown cementation and annually thereafter. Examinations included an assessment of implant/crown immobility, presence/absence of pain, plaque scores, bleeding on probing to a depth of 2 mm, and the recording of any adverse biological or technical events. Radiographs were taken using a standardized paralleling technique with an Eggen film holder. The distances from the implant reference point at the base of the coronal bevel to the first point of bone-to-implant contact as determined at x7 magnification was recorded on the mesial and distal of each implant. Finally patient were asked to score the esthetics and function of the crown at the 3- and 10-year review on a 100 mm VAS scale where 0 = dissatisfied and 100 = very satisfied. Statistical analysis using paired and unpaired t-tests was undertaken to determine the influence of time and protocol respectively on the resultant marginal bone levels.

**Results:** While some patients were absent from the occasional annual review all patients were seen across the study and only one patient missed the final review although this patient was available for telephone interview to confirm that nothing had changed from the previous review. Thus it was possible to confirm a 100% survival rate for implants and a 90% survival rate for crowns, with 2 crowns having to be replaced during the study. With regard to adverse events, one patient presented with a mucositis at the 10-year review, two crowns required re-cementation, three crowns fractured one of which required replacement and two abutment screws came loose and required re-tightening, one of which resulted in the need for a new crown. Patients scored a mean of 9.4 for function at 3 years which reduced to 8.4 at 10 years and 9.3 at 3 years reducing to 7.6 at 10 years for esthetics.

At the 10-year review the mean marginal bone loss measured 0.64 mm in group EP and 0.86 mm in group DP, there was no significant difference over time or between the groups for any of the clinical or radiographic parameters assessed.

**Discussion and Conclusions:** Results of the current study corroborate the findings of previous systematic reviews with respect to both implant and crown survival. The maintenance of marginal bone in the current study was superior to that anticipated by established criteria, while technical complications with the crown appeared more consistent with previous studies. However the use of the more robust prepable abutment appeared to resolve the problems of decementation and abutment screw loosening. It can be concluded that the Astra Tech implant is well suited to single-tooth replacement and that patient scores for function and esthetics, while reducing over time, remain high even after 10 years.

# A prospective 5-year study of fixed partial prostheses supported by implants with machined and $TiO_2$-blasted surface

**Gotfredsen, K.**
**Karlsson, U.**

**J Prosthodont**
2001;10, 2-7

**Purpose:** This prospective study set out to record and compare Astra Tech implants and the marginal bone loss at implants with a machined (M) and a roughened (TiOblast™, TB) surface when used to support fixed partial prostheses over a 5-year follow-up period.

**Materials and Methods:** 50 patients were enrolled in the study and presented with partially edentulous spans of at least one year standing. In the maxilla 45 implants were placed (M = 25 and TB = 20) and 83 implants were inserted into the mandible (M = 39 and TB = 44). Each patient received the two surface types alternately to allow a within patient comparison. Equal numbers of the two surface types were placed (n = 64/surface). Surgery was performed according to manufacturer's recommendations with a submerged healing of 3 to 7 months depending on the jaw. At abutment connection the standard Uni-Abutment was connected. All partial prostheses were screw-retained and insertion was always within two months of postoperative healing at which time baseline radiographic and clinical data was recorded.

Clinical data was collected annually and included assessment of mobility, parasthesia and inflammation (defined according to a protocol). Any technical complications with either the components or prostheses were also noted. In addition patients were independently asked to grade function and esthetics as good, moderate or poor.

Intra-oral annual radiographs were taken in a standardized manner. Marginal bone levels were assessed by an independent radiologist to determine the amount of bone loss on the mesial and distal surfaces of each implant to the nearest 0.1 mm. Statistical analysis was performed at the end of the 5-year recall to determine the difference between survival rates and marginal bone loss for the two implant surfaces. In addition, one implant of each type was selected for each patient to allow a within patient comparison.

**Results:** Ten patients with 16 implants were lost to follow-up. Over the five year study period 3 machined implants failed resulting in cumulative survival rates of 95.1% and 100% for M and TB implants respectively. Mean marginal bone loss measured 0.21 mm and 0.51 mm for M and TB implants respectively with only 5 implants recording a bone loss of > 2.0 mm. These differences were not statistically significant. At the end of the study period, 6% of both types of implant were associated with mucosal inflammation.

With regard to technical complications only 2 abutments fractured within 2 years of function. Five abutments required retightening. A total of 12 bridge screws in 7 patients required retightening and 2 bridges were remade. 100% of patients recorded the function as good and 79% recorded the esthetics as good at the 5-year recall.

**Discussion:** The current study demonstrated survival rates for both machined and $TiO_2$-blasted Astra Tech implants which fall well within the criteria for success set out by Albrektsson et al. There were 3 failures, all of which were implants with the machined surface. In regards to change in marginal bone level between the two groups differences were not statistically significant and fell well within established criteria for success. The most common technical problem of bridge screw loosening was restricted to prostheses supported by two implants only.

# A split-mouth comparative study up to 16 years of two screw-shaped titanium implant systems

**Jacobs, R.**
**Pittayapat, P.**
**van Steenberghe, D.**
**De Mars, G.**
**Gijbels, F.**
**Van Der Donck, A.**
**et al.**

**J Clin Periodontol**
2010;37(12):
1119-1127

**Purpose:** The aim of the study was to compare the long-term outcome of 2 different implant systems having either a machined or a rough implant surface utilizing a randomized split-mouth design. The primary variables were changes in marginal bone levels and bone densities over time.

**Material and Methods:** Patients with bilateral posterior edentulism seeking for treatment at either the Department of Periodontology or the Department of Prosthetic Dentistry (University Hospitals, UZ KU Leuven, Leuven, Belgium) were screened for inclusion. Inclusion and exclusion criteria are presented in the 2-year follow-up report (van Steenberghe et al 2000) and follows general criteria for implant treatment including patient's signed informed consent and having Kennedy Class-1 in the upper or lower jaw. In total 18 patients were included.

The Astra Tech Implant System™ with the TiOblast™ surface, a smooth neck design, a diameter of 4.0 mm, and varying lengths, was used on one edentulous side. On the other side, each patient received the Nobel Biocare Brånemark System implants™ which had a machined surface, a diameter of 3.75 mm, and varying lengths. The implants were left submerged for 5 months before abutment surgery took place and final delivery of screw-retained fixed partial ceramometal dentures was performed.

Following prosthetic delivery, i.e. baseline, clinical and radiological assessments took place at annual recalls. Sulcus bleeding index (Mühlemann & Son, 1971), presence of plaque (yes/no), probing pocket depth were recorded as well as marginal bone levels as measured from intra-oral radiographs. The mesial and distal bone levels were measured from the reference level to the first bone-to-implant contact using Adobe Photoshop software. Bone densities were evaluated at the mesial and distal sides by using Densito® Software. The periotest value (Siemens AG, Bensheim Germany) was recorded at the 1 and 10-year follow up. A prosthetic evaluation was also conducted including the recording of complications, porcelain chipping retightening of abutment or bridge screws etc.

Statistical analysis was performed using Statistica Windows software with a p-level set to 0.01. The analyses were performed on patient and implant level and a linear regression analysis was performed in order to reveal changes over time for marginal bone levels and pocket depths. Differences between the two systems were analyzed by Wilcoxon matched pair test.

**Results:** Only 1 Brånemark System implant failed and it occurred before the prosthetic connection. Hence the cumulative implant survival rate was 97.7% for the Brånemark System and 100% for the Astra Tech Implant System, after 16 years in function. A 100% bridge survival was noted. Porcelain chipping and screw retightening occurred at 3% and 8%, respectively. There were no differences between the implant systems in terms of probing pocket depth or bleeding on probing at any time point. The patients oral hygiene was good during the entire follow-up period in most patients. The periotest values were similar between the systems and decreased from 1 year to 10 year whereas radiographic bone density increased with 8.2% at Astra Tech implants and 7.7% at Brånemark implants during the same period. The mean marginal bone loss after 16 years was 0.02 ± 0.45 mm at Astra Tech implants (n=24) and 0.31 ± 0.69 mm at Brånemark implants (n=23) with the implant as the statistical unit. Patient level analysis (n=9) revealed a mean marginal bone loss of 0.03 ± 0.27 mm at Astra Tech implants and 0.02 ± 0.26 mm at Brånemark implants. The bone loss did not differ significantly from baseline values or between the systems at any time point. It was however noted that the bone level at Astra Tech implants was located closer to the implant abutment junction, at a distance of 0.4 ± 0.59 mm, while the corresponding figure was 1.79 ± 1.06 mm for the Brånemark implants. When measuring the bone loss at neighboring teeth (distal side) it was found that on average 0.5 ±0.7 mm bone was lost during the follow-up period.

**Discussion and Conclusion:** Clinical and radiographic parameters remained stable during the entire 16 year follow-up period and were not different between the systems. Surface topography had thus no effect on hard and soft tissue variables in this randomized split-mouth clinical trial. These results are similar to what has been reported previously in other long-term clinical studies on Astra Tech implants.

# A 5-year prospective study of Astra single tooth implants

**Palmer, R.M.**
**Palmer, P.J.**
**Smith, B.J.**

**Clin Oral Impl Res**
2000;11, 179-182

**Purpose:** To evaluate the Astra Tech single tooth implant system over a 5-year follow-up.

**Material and Methods:** 15 patients each received one Astra Tech ST implant (Ø 4.5 mm). 11 implants were short, measuring 11 mm and four measured 15 mm in length. Implants were placed according to recommended surgical protocol with the head of the implant 2 to 3 mm apical to the cemento-enamel junctions of the adjacent teeth. In total 6 central incisors, 8 lateral incisors, and 1 bicuspid were replaced. No additional ridge expansion or grafting procedures were used for any implants.

All implants were left to osseointegrate for 6 months prior to connection of the 0.0 mm ST abutment in 12 cases and the 1.0 mm ST abutment in 3 cases. Implants were temporized either with the ST coping or a temporary crown. Ceramometal definitive crowns were placed as early as possible. Patients were followed-up every 6 months to determine clinical stability of the crown and tissue health.

Radiographs were taken using a long-cone technique at crown cementation and annually thereafter, and were assessed at x7 magnification. Marginal bone level was measured with reference to a defined point at the top of the implant. Results were subject to statistical analysis.

**Results:** One patient was lost to follow-up. For the remaining 14 patients all attended their review appointments.

No implants have been lost and there have been no soft tissue problems and minimal bleeding on probing. Prosthetically there have been no recorded cases of abutment screw loosening. One crown has decemented and required recementation after 18 months. One further crown suffered porcelain fracture and required replacement.

Mean distance for the marginal bone level measured from the reference point to the most coronal bone to implant contact point was at crown cementation (baseline) 0.46-0.48 mm. No statisticaly significant change occurred in bone levels to the 5-year follow-up (0.36-0.43 mm at 5 year). 33% of implants measured no bone loss and in some cases there was a clear bone gain.

**Discussion and Conclusion:** The Astra Tech single tooth implant system was most effective at replacing missing teeth.

The system was simple to use and there were very few complications. All implants remained in function and screw joints remained stable throughout the study. Excellent soft tissue health was maintained around all implants.

Marginal bone levels were extremely well maintained over the 5-year follow-up and may be attributable to the TiOblast surface and MicroThread design of the coronal portion of the implant.

# A 10-year follow-up study of titanium dioxide-blasted implants

**Rasmusson, L.**
**Roos, J.**
**Bystedt, H.**

**Clin Impl Dent Rel Res**
2005;7, 36-42

**Purpose:** This prospective study set out to evaluate the 10-year cumulative survival rate and marginal bone levels at 199 $TiO_2$-blasted implants.

**Materials and Methods:** Patients with either edentulous maxillae or mandibles were enrolled in the study on a consecutive basis. Patients with uncontrolled diabetes, alcoholism, irradiation or mental illness were excluded. Smokers (n = 4) were included. Of the 36 patients enrolled, 28 were available for their 10-year follow-up, with a total of 155 implants.

Implants (TiOblast™ 3.5, 4.0) were inserted according to manufacturer's recommendations and benefited from a submerged healing protocol of 3 to 6 months, at which time they were exposed for the connection of 20° UniAbutments.

Intra-oral radiographs were taken using a paralleling technique both at baseline (insertion of prosthesis) and annually thereafter. Radiographs were analyzed using image capture software. All bone levels were measured with respect to the implant reference point at the base of the most coronal bevel. All bone levels above this reference point were recorded as zero.

A life table was constructed which would compensate for the lost data and give a better reflection of the likely 10-year outcome for these implants.

**Results:** During the study observation periodonly 6 implants were lost, 3 of which were mandibular and 3 maxillary. All failures were early losses identified at abutment connection. The cumulative survival rate for all implants was 96.9% and for maxillary implants alone this figure was 96.6%.

There were few prosthetic complications and bridge screw fracture only occurred in one patient, and this was attributed to an ill-fitting framework. After a complete re-make no further screws broke in this or any other patient. Survival rate of the superstructures was 100% after 10 years.

Soft tissues were recorded as healthy with an absence of bleeding on probing in greater than 90% of all sites.

For the 100 first inserted implants, marginal bone loss data revealed a mean of 1.27 mm from the reference point at the 7-year follow-up.

**Discussion and Conclusion:** This study represents the first 10-year follow-up for implants with a microtextured surface of the order of 1.10 µm.

The cumulative survival rate was impressive being 97.2% for mandibular implants and 96.6% for maxillary implants, which is better than rates recorded for machined implants. In addition it is noteworthy that all failures were early, and no late failures were recorded. It can be speculated that TiOblast implants therefore perform better in low-density bone. The annual bone loss rate equates to 0.15 mm/year suggesting marginal bone remains stable at these microroughened surfaces. Furthermore the incidence of soft tissue complications appears to remain very low, which is likely a function of the conical implant/abutment joint design.

# Effect of surface topography of screw-shaped titanium implants in humans on clinical and radiographic parameters: a 12-year prospective study

**Vroom, M.**
**Sipos, P.**
**de Lange, G.**
**Gründemann, L.**
**Timmerman, G.M.**
**Loos, B.**
**van der Velden, U.**

**Clin Oral Impl Res**
2009;20(11) :1231-1239

The application of moderately rough surfaces was introduced on the basis that it would help to promote stronger interfacial shear strength (osseointegration) as measured by resistance to removal torque, a higher percentage of bone-to-implant contact and thus lower maximum bone stresses. It is postulated that this would ultimately result in better maintenance of marginal bone levels. In addition it was proposed that in contrast to very rough surfaces such as titanium plasma spray, these moderately rough surfaces would not give rise to significantly more peri-implant infections than a normal machined surface.

**Purpose:** The current study was set up as a double blind randomized prospective clinical and radiographic study to compare the marginal bone response and status of the peri-implant soft tissue for moderately rough and machined surface implants of identical geometry, placed into the same patients and monitored for up to 12 years.

**Material and Methods:** Twenty edentulous patients with a mean age of 53 years were enrolled to the study. Alcohol and drug abuse, uncontrolled diabetes, local pathology of the jaws and bruxing were exclusion criteria. Smokers were included. All patients received 4 implants, 2 Astra Tech TiOblast™ implants and 2 Astra Tech machined implants which were placed into the anterior mandibular jaw, mesial to the mental foramen using randomized assignment of surface for the first implant at the left premolar site followed by placement of alternate surfaces thereafter. Implants were submerged and subsequently exposed approximately 4 months after placement and definitively restored by means of a bar and overdenture construction.

All patients were subject to both clinical and radiographic follow-up at baseline, 6-months post prosthesis insertion and then annually for 5 years thereafter. A further follow-up was undertaken after 12 years. Clinical parameters included plaque index (Silness & Löe 1964), presence or absence of calculus, bleeding on probing (van der Weijden 1994), pocket depth, and the analysis of the location of the gingival margin. Measurements was performed at four sites around each implant by the same examiner, who was blinded as to the surface type of the implant. All measurements were repeated at 10% of sites to assess intra-examiner variability.

Intra-oral long-cone radiographs were taken using a standardized technique with individualized film holders for the left and right sides of each patient to ensure reproducibility of radiographs. Devices were secured directly to the individual abutments to rule out any variability in positioning. Images were digitized and linear measurements taken from the implant/abutment junction to the most coronal bone-to-implant contact to the nearest 0.01 mm. Measurements were compared from the 6-month, 1-, 5- and 12-year reviews. Again intra-examiner reproducibility was assessed.

**Results:** Only 2 machined implants failed to osseointegrate and these were replaced and the replacement included in the follow-up analysis. All implants remained in function at the 12-year review. 7 patients were lost to follow-up. Most of the clinical parameters remained stable from baseline to the 12-year review with mean plaque scores ranging from 0.19 to 0.39, little or no evidence of calculus, bleeding scores ranging from 0.2 to 0.55, gingival zenith ranging from 1.63 mm to 2.4 mm and pocket depth ranging from 2.25 to 2.82 mm. There was no evidence of any influence by surface type on these clinical parameters. For turned implants the mean marginal bone loss measured -0.04 mm at baseline and decreased (i.e. bone gain) to +0.01 mm (±SD 0.5) at the 12-year review. Similarly for TiOblast implants, baseline bone loss measured – 0.08 mm compared to +0.01 mm (±SD 0.58) at the 12-year review. There were no significant differences between surface type within any time frame or across the entire study period.

**Discussion and Conclusions:** The current study was established to provide robust evidence of the influences exerted by surface topography on the hard and soft peri-implant tissues, via a randomized, double blinded clinical trial in which patients received both surface types, thus removing the patient as a confounding variable. Furthermore the use of screw-retained customized film holders significantly reduced the influence error when comparing images for linear measurements. It can therefore be concluded that for this data set from edentulous patients there is no difference in soft or hard tissue changes around machined or TiOblast implants, and that the latter are no more susceptible to peri-implant infections than the machine implants.

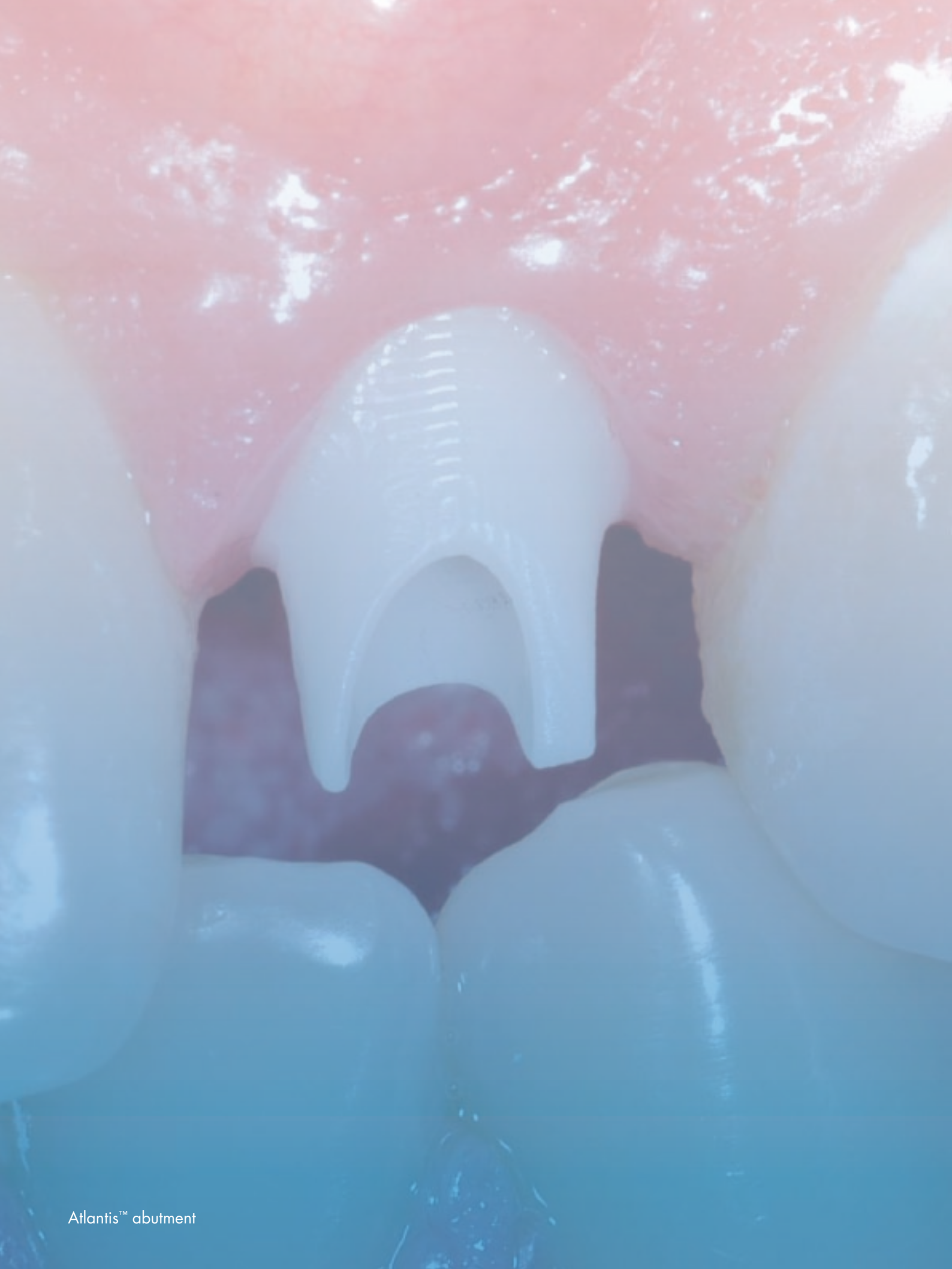

Atlantis™ abutment

# Atlantis™

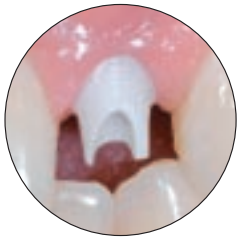

Atlantis™ is the patient-specific abutment for all major implant systems. The abutments are designed from the final tooth shape using unique software, enabling the production of milled titanium and zirconia abutments.

# Marginal integrity of direct and indirect castings of implant abutments

**Ganz, S.D.**
**Desai, N.**
**Weiner, S.**

**Int J Oral Maxillofac Implants**
2006;21(4):593-599

**Purpose:** The purpose of this study was to measure and compare the marginal gap size (accuracy) of metal copings fabricated on direct i.e. computer-milled abutments (CMA), or with indirect technique i.e. on epoxy and stone dies. This in order to evaluate if the Atlantis technique has clinical advantages such as reducing the steps (positive-to-negative transformations) in implant laboratory restorative procedures.

**Materials and methods:** Ten computer-milled abutments were used in the experiment. They were milled from a block of commercially pure titanium into a standardized premolar shape (mesial-distal width of 7 mm, bucco-lingual width of 8 mm, 10º occlusal convergence, 11 mm high and the apical 3 mm serving as the collar). 5 Atlantis abutments were placed on each side on implant analogs positioned in a jaw model only having the incisors left for orientation.

After impression with vinyl polysiloxane material two full arch working casts were produced.

The casts which had removable dies, were made of epoxy resin and type IV die stone. Marginals were exposed after careful trimming. Casts in type III alloy were then made for all three modeling techniques, a) directly on the titanium computer-milled abutments coated with 2 layers of die spacer prior to wax up and casting; b) indirect wax ups on the epoxy resin dies coated with 3 layers of die spacer; c) indirect wax ups on the stone dies coated with 2 layers of spacer and casting. The castings were cleaned and fitted to respectively epoxy or stone dies, or if computer-milled fitted to the abutment prior to analysis. At imaging in the microscope (60X Olympus SZX12 equipped with a USB camera) a custom built holder was used fixating the abutment and castings (a finger pressure level) to ensure complete seating. The images were analyzed with a specialized imaging and measurement software program (Bioquant 2000, Biometrics) at five uniform sites along the marginal interface. A mean marginal gap value was calculated for each casting, and was compared using a 1-way analysis of variance and pair-wise comparison (Scheffé test). Additionally, casts made from epoxy and stone dies were photographed and measured as controls.

**Result:** A comparison of the marginal gap of metal copings between indirectly made dies (on epoxy and stone) and those made directly on duplicate abutments was performed. Further, in order to reveal the quality of the CMA, the gap at copings seated on the abutment from which they were waxed were compared with the gap after transfer to a duplicate abutment. The castings made from direct technique had the smallest mean marginal gap ($P \leq 0.001$). The gap was not significantly changed when these casts were transferred to the duplicate abutment. The result for the direct technique was clinically acceptable. Using the indirect technique resulted in larger gap sizes irrespective of die material (epoxy or stone). The marginal gap of indirect castings were also larger on casts from epoxy dies compared to stone dies.

**Discussion:** The uncertainty of the impression steps and provisional abutment can be avoided with an even higher accuracy of the final cast when using the Atlantis technique. The result from this study show that computer-milled abutments can be duplicated with sufficient accuracy and allow an exchange of casting between the original abutment and the duplicate abutment. In the clinic this result in shortened treatment time, increased fit and reduced number of laboratory remakes.

# A comparison of fabrication precision and mechanical reliability of 2 zirconia implant abutments

**Kerstein RB, Radke J.**

**Int J Oral Maxillofac Implants**
2008;23(6):1029-36

**Purpose:** Published studies indicate that zirconia is a reliable implant abutment material. Zirconia possesses several positive characteristics such as biocompatibility, favourable color and mechanical properties, which makes the material suitable for use in modern dentistry. The purpose of the study was to compare fabrication precision and fracture strength of two types of commercially available zirconia abutments; the Atlantis™ Abutment Zirconia (Astra Tech) and the Procera AllZirkon abutment (Nobel Biocare).

**Material and Methods:** Twenty-nine abutments of each type (Atlantis and Procera AllZirkon) were created by their respective manufacturers to fit a Brånemark System implant with external hex, diameter 4.0 mm (Nobel Biocare). Ten abutments of each type were randomly selected for precision measurements using a coordinate measuring machine with a small-diameter touch probe (Brown and Sharpe, North Kingston, USA). The following dimensions of the abutment interface area were recorded in order to evaluate fabrication precision: hex dimensions (mean of three measurements of opposite hex walls), bore diameter concentricity, mean counterbore diameter, and mean true position of the counterbore to bore.

The remaining specimens were used to measure fracture strength, and to analyze fracture origin and propagation characteristics. Each test specimen (connected implant and abutment) was loaded in a standardized testing machine (Instron Corporation) in an angled manner, simulating maximum implant-abutment misalignment and off-axis loading. Increasing loads were applied until fracture of the specimens. Maximum failure load was recorded and the probability of failure was evaluated for the two abutment types. Next, the characteristics (location and nature of fracture origin) of the fractures were analyzed.

**Results:** The calculations performed on the fabrication precision of the abutment interface determined that there were no statistically significant difference between the two abutment designs. The mean load to fracture values were 831±69 N for the Atlantis abutments and 740±96 N for the Procera AllZirkon abutments. This difference was statistically significant. Furthermore, the load to failure data demonstrated a higher probability of failure for the Procera AllZirkon abutment compared to the Atlantis abutment under intraoral occlusal loads.

Scanning electron microscopy analyses of the fractures showed that fracture origins for both types of abutments were typically small irregularities in the as-processed surface. However, the analyses revealed noticeable differences in the crack propagation between Procera AllZirkon and the Atlantis abutment, with the Atlantis abutments showing consistent fracture origin of the inner hex interface surface for all test abutments. The fractured surface appeared smooth and continuous throughout the fractured surface. The Procera AllZirkon, on the other hand, exhibited fracture origin at the radius inside the hex, and the fractured surface was visibly irregular.

**Discussion and Conclusions:** The authors conclude that both types of zirconia abutments showed failure loads exceeding maximum human bite force, however, mean load to failure was significantly higher for the Atlantis abutment compared to the Procera AllZirkon abutment. In addition, the Atlantis abutment showed a statistically significant higher probability to survive occlusal loads. There were no significant differences between the interface features measurements for the two abutments types. The difference in strength would therefore most probably not be related to the precision of the respective fabrication process, but rather a result of the raw stock material that each company uses in its abutment fabrication process.

# Utilizing computer-generated duplicate titanium custom abutments to facilitate intraoral and laboratory implant prosthesis fabrication

**Kerstein, R.B.**
**Osorio, J.**

**Pract Proced Aesth Dent**
2003;15:311-314

**Background:** Patient specific or custom made abutments assisted by computer design and computer manufacturing (CAD/CAM) can predictably be formed with the desired marginal contour, orientation and morphology. The Atlantis concept further allows for the correct anatomical gingival formation at the prosthetic margin (first set of abutment) and for the simultaneous prosthesis fabrication using an exact duplicate abutment (second set of abutment).

This article describes the methodology of CAD/CAM fabrication of implant prosthesis utilizing abutment duplicates. The technique offers significant advantages compared to he conventional single abutment technique.

**Concept:** The CAD/CAM abutments are machine milled out of a solid titanium block. The Atlantis concept includes the production of a second "virtual abutment" obtained from the same data file from the master stone cast. This virtual abutment can be produced repeatedly with the exact dimensions. The first abutment is connected to the implant at second stage surgery and used as a healing abutment, while the second works as a laboratory master die. Enhanced laboratory accuracy is obtained when material distortions in impression materials and stone dies are avoided. Furthermore, the marginal accuracy of the abutment fit to the implant is improved since the abutment is milled and not a result of a cast.

In a clinical example a full upper arch rehabilitation is indicated due to lost function and esthetics.

The provisional dentures were scanned in order to resemble the anatomical form and geometry of the final restoration. Thereafter the master stone cast with the implant analogs was scanned. The CAD program then compared the two scans in order to optimize the design of the abutments and a final milling of a titanium block was performed. One set of abutments to fabricate the provisional restorations (which was the original full denture) and to control the tissue shape. The other set of abutments functioned as laboratory dies for metal framework fabrication and ceramic application.

**Conclusion:** The current "state-of-the art" in custom-made abutments utilizes CAD/CAM technology to design and mill abutments. Since the information is stored in computer files duplicates can be produced. In this case, a set of abutments is used intraorally for the soft tissue and also to support the temporary construction, while the other set is used to fabricate the final restoration. Significant advantages over the conventional single abutment technique are offered.

# Computerized milled solid implant abutments utilized at second stage surgery

**Schneider, A.**
**Kurtzman, G.M.**

**Gen Dent**
2001;49:416-420

**Background:** Rotational forces at single crowns are a great challenge in terms of the tightening of the abutment head against the implant platform. Lateral forces (i.e. all forces not axially) also challenge the restoration especially in the upper anterior situations, where the implant often is placed in a protruded angle. Material components fatigue and loosening may occur. Currently three types of abutments exists: stock, UCLA and computer-milled abutments. The prefabricated stock abutments may be milled at the office or at the laboratory and are available as straight or in pre-set angles. These abutments do not allow for major adjustments, because the angles are fixed and the width cannot be enlarged. The second type of abutment is the UCLA type which is a laboratory wax and cast gold alloy abutment. The precision fit of the all plastic abutment to an implant can never be as high as for milled abutments. However, there are milled UCLA abutments with a wax and castable sleeve but these can have limited mechanical properties. Computer-milled abutments can achieve ideal strengths without the compromise of the abutment head. Furthermore, the precision of marginal fit is increased with milled abutments compared to cast abutments.

The Atlantis abutment concept works from a master cast of the patient (impression and index), retrieving additional information from pre-determined land marks. At the laboratory, implant analogs are incorporated in the master cast and the computer assisted design of the ideal abutment takes place. The final design file is transferred to a computer controlled precision milling machine for the manufacturing of the whole solid titanium abutment. The abutment can be produced in exact duplicates with or without a temporary construction. If no adjustments are required at try-in, the final construction can be manufactured without an additional impression.

**Case report:** A sport related trauma in the upper canine position served as indication for a 2-stage implant therapy. At second stage surgery a healing abutment was placed and the area was left to heal for 7 days. Impressions were then taken of the full arch with a transfer coping seated on the implant.

The impression tray (holding the transfer coping) was sent to Atlantis for duplicate abutment fabrication. At delivery, both abutments were tried-in, with extra emphasis of the marginal contour. One abutment was used to support the temporary crown and the other was returned to the lab for the production of a porcelain-fused-to-metal crown. At try-in of the final crown, X-ray confirmed seating, and finally the crown was cemented.

**Conclusion:** The Atlantis abutment offers ideal abutment shape and profile, simplifying the prosthetic portion of the treatment and improving the esthetic result. The head on the Atlantis abutment is stronger than on the cast UCLA abutment which can be of importance as more forces are brought to the platform area. The solid standard titanium abutments have a long-term success documented over 30 years. Hence, the Atlantis abutment which is also milled from a solid titanium block is therefore expected to have similar good long-term results.

# Cresco™

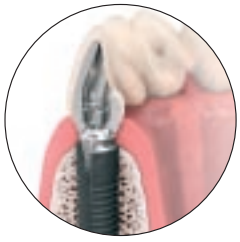

Cresco™ is the easy-to-use solution for screw-retained implant bridges, providing freedom and a perfect fit every time. Cresco is available in different framework materials for all major implant systems. The technique is carefully described and clinical result are presented in the following summaries.

# A prospective 5-year multicenter study of the Cresco implantology concept

**Helldén, L.**
**Ericson, G.**
**Elliot, A.**
**Fornell, J.**
**Holmgren, K.**
**Nilner, K.**
**Olsson, C.**

**Int J Prosthodont**
2003:16, 554-562

**Purpose:** The aim of this study was to evaluate the clinical and radiographic outcome for implants restored with an abutment-free passive fitting Cresco bridge.

**Material and Methods:** The implants used in the current study were the Cresco API implants presenting with an acid etched surface and an internal conical interface with a 45-degree taper allowing for implant mal-alignments up to 90 degrees. Implant diameters were 3.3 mm, 3.7 mm and 4.5 mm. No abutments were utilized in the system; rather a definitive metal framework was fabricated to derive direct connection to the implants by means of 2mm diameter connecting screws.

Fixture-head impressions allow for plastic mouldable sleeves to be connected to the replicas and bent into the long axis of the teeth, with occlusal access being placed favourably within the occlusal table or palatally for anterior implants. Off-set angles of up to 17 degrees can be corrected in this way. Subsequent to registration of the cylinder positions in an articulator-like "fixator", prefabricated titanium cylinders are then used to replace the plastic sleeves and these milled parallel to the opposing cast titanium framework to which they are then laser welded to ensure a passive fit.

A total of 60 patients were treated by means of a two-stage surgical approach at 3 centers, for the rehabilitation of 6 edentulous maxillae, 11 mandibles and 43 partial saddles of which 32 were mandibular. Of the patients enrolled only 52 were available for follow-up at 5 years.

A full preoperative assessment included an evaluation of bone density and volume according to the Lekholm/Zarb classification. Patients were followed up at 12 and 18 months and then at 2 , 3, 4, and 5 years in order to evaluate the presence of any symptoms and to assess soft tissue health, implant stability, mechanical stability and changes in marginal bone levels as determined from intra-oral radiographs taken in customised paralleling devices. Radiographs were critically appraised to the nearest 0.1mm at x7 magnification with an in-built millimetre graticule.

**Results:** A total of 215 implants were utilized in the study of which 4 failed to integrate, and a total of 211 were available for review at the 5-year follow up. Patients reported a high level of satisfaction with the only symptoms related to minor soft tissue problems, which was reflected in a general healthy soft tissue scoring with only 15% of sites recording bleeding on light pressure. There was no evidence of peri-implant infections.

Three retaining screws fractured after 21 months in one subject restored with a full mandibular fixed bridge, and 2 screw fractured in one subject restored with a 3-unit FPD. This patient had been totally unaware of the bridge mobility and had failed to attend the previous follow-up. Unfortunately both the prosthesis and 2 implants thus required removal. This gave an implant survival rate after loading of 98.5%, and a prosthesis survival rate of 98.1%.. Resin fracture occurred in 2 cases, and one laser welded joint fractured requiring laboratory repair.

Mean marginal bone loss measured 0.3 mm after 5 years of function.

**Discussion:** The current study was meant to evaluate the Cresco concept giving due consideration to both the implant and restorative components, to be evaluated over a 5 year time frame. In this respect the clinical and radiographic outcome demonstrated the Cresco system to be comparable to other systems reported. The flexibility of the Cresco system allows for the realignment of screw access holes up to 17 degrees, aiding their relocation away from the buccal surface when implants have a buccal inclination and also ensuring a more passive framework fit. The current study would support this with a very low rate of mechanical problems with less than 2% of problems related to the retaining screws after 5 years of function.

The radiographic follow-up certainly demonstrates a marginal bone maintenance that fulfils currently accepted criteria for success, giving an implant survival rate of 98.5% which is comparable to other marketed implant systems. It can therefore be concluded that the current 5-year results demonstrate that the Cresco system is efficacious in the restoration of partially and fully edentulous jaws.

# Early loading of Astra Tech OsseoSpeed implants placed in thin alveolar ridges and fresh extraction sockets

**Oxby, G.**
**Lindqvist, J.**
**Nilsson, P.**

**Appl Osseointegration Res** 2006;5, 2-6

**Purpose:** Preclinical documentation has provided supporting evidence that the modification of a $TiO_2$ grit-blasted surface with fluoride leads to enhanced bone-to-implant contact with increased resistance to shear and tensile forces. In addition it is proposed that this OsseoSpeed™ surface promotes faster bone-to-implant contact.

The following report presents the interim data from the early clinical outcome of patients treated in a prospective clinical trial with OsseoSpeed™ implants in immediate extraction sockets and healed sites.

**Material and Methods:** A total of 18 patients, 9 male and 9 female were enrolled in the study receiving a total of 65 implants into both healed (n = 36) and immediate extraction (n = 29) sites. Both maxilla and mandible were treated in a 60/40 ratio. Patients were free of systemic disease, with no obstacles to surgery under local anesthesia. For extraction sockets the implants were located 1 mm below the buccal crest, placing them deep to the interproximal and lingual crest of bone. For healed sites, where ridges were generally narrow, a deep placement was also utilized to avoid too much thread exposure. Where dehiscence or circumferential socket defects remained a mix of bone from the BoneTrap™ and bio-glass was used as a graft.

For implants to remain included in the study an adequate primary stability was necessary for early functional restoration within 3 months of placement. Impressions were typically taken 2 weeks post-op and prostheses inserted within 5 weeks of surgery as a mean. Prostheses included single-tooth replacements as well as screw-retained partial and full arch prostheses, fabricated utilizing the Cresco™ method.

Follow-up was staged at 6 and 12 months post insertion of the final prostheses, with standardized radiographs used to compare measures of the bone level to a fixed reference point at the base of the coronal bevel of the implant with those recorded at baseline, on prosthesis insertion. All assessments were undertaken at x7 magnification to the nearest 0.1 mm. Clinical follow-up also included an assessment of plaque score, mucosal index, pocket probing depths and registration of any mechanical problems.

**Results:** One implant was lost due to infection giving a 1-year survival rate of 98.5%. For 78% of sites there was no evidence of mucosal inflammation, with generally good plaque control. There was no discernable peri-implant mucositis as evidenced by deep pocketing or radiographic evidence of bone loss, with changes in the marginal bone level of 0.1 mm from baseline to the 1-year follow-up. Furthermore there were no differences between the groups for implants in healed sites or extraction sockets.

In addition it was of interest to note that there were no mechanical problems recorded, and no episodes of screw loosening with the Cresco™ Precision prostheses.

**Discussion and Conclusions:** Unlike previously published data there was no evidence in the current study of any early bone loss which could be attributed to the new fluoridated surface technology. However it is recognized that it is difficult to extrapolate radiographic interpretation of bone levels to the real situation due to their 2-dimensional nature and in the current study due to the difficulty in differentiating between native bone and the graft, when used. Nonetheless within the context of previous studies, which use the same methodology, and in light of the absence of clinical signs of inflammation or pocketing the data is encouraging.

In addition it is very encouraging to note that prostheses could be connected to the implants as early as 5 weeks post insertion, secured to 25 Ncm without inducing early failure due to stresses from non-passive frameworks. This is certainly due to the accurately fitting Cresco™ Precision prosthetic method, which ensures absolute passivity of fit.

It can be concluded that OsseoSpeed™ implants can be subjected to early loading when restored with Cresco™ Precision fit prostheses.

# Evaluation of the marginal precision of one-piece complete arch titanium frameworks fabricated using five different methods for implant-supported restorations

**Torsello, F.**
**di Torresanto, VM.**
**Ercoli, TC.**
**Cordaro, L.**

**Clin Oral Impl Res**
2008;19(8):772-779

Considerable differences of opinion exist in the literature as to whether a marginal discrepancy of fit between prosthesis and supporting abutments causes biological complications. However there is consensus that cast frameworks do not fit as precisely as milled structures and in addition the use of titanium is thought to be preferable to cast gold with respect to tissue response possibly due to the absence of galvanic reactions.

**Purpose:** To compare the marginal accuracy of fit of full arch splinted frameworks fabricated using 1) the lost-wax casting technique(LWC) with burn-out cylinders, 2) cast frameworks laser-welded to prefabricated titanium cylinders (LWP), 3) a Procera® milled framework (PMF, Nobel Biocare), 4) the Cresco™ Ti system (CTS, Astra Tech), and 5) the CAMStructSURE® precision milled bar system (CAM, Biomet 3i).

**Materials and Methods:** Patients who had received 5 to 9 ITI Straumann implants and were due to have a total of 15 full arch reconstructions with cross-arch splinted titanium restorations were enrolled to the study and randomly assigned to one of the five groups LWC, LWP, PMF, CTS, and CAM. The methodology for each of the 5 techniques has been described elsewhere. Frameworks in the LWC and LWP groups were cemented restorations while the restorations fabricated in the other groups were all screw-retained. All structures were designed to be metal-ceramic except for those in the CAM group which were due to be metal-acrylic. To be most representative of normal working procedures the frameworks were all fabricated by technicians unaware of the intended study, thereby allowing for all possible laboratory errors. The fit of each framework was measured directly on the master working cast, prior to delivery to the patient using stereomicroscopy at 100x magnification. Measurements were made at 4 sites on each abutment replica (91 implants, total 364 measurements) and means and standard deviations calculated. Statistical analysis using ANOVA was performed to determine the presence of any differences at the 95% confidence level.

**Results:** With respect to marginal integrity of fit the groups performed with decreasing accuracy and increasing gap width as follows: CTS (18 µm) > PMF (21 µm) > CAM (27 µm) > LWP (33 µm) > LWC (78 µm). There was a significant difference between the pooled groups, $p < 0.01$ although there was no significant difference between CTS, PMF, and CAM techniques. The lost-wax casting technique (LWC) was significantly less accurate when compared to all other groups, $p < 0.01$ and the laser-welding technique to prefabricated copings (LWP) was significantly less accurate than the PFM technique, $p < 0.05$ and the most accurate technique using the Astra Tech Cresco TI system™ (CTS), $p < 0.01$. In addition the LWC technique yielded the widest standard deviation while the CTS technique yielded the lowest deviation. In the former the largest gap was as much as 300 µm in width compared to the smallest gap measured which was only 10 µm with CTS.

**Discussion and Conclusion:** It has previously been demonstrated that that while the lost-wax casting technique has served the dental community well for many years, it does not offer the accuracy of fit achieved with milled structures, especially when employing titanium since this metal is more difficult to cast accurately. The introduction of laser-welding of frameworks to prefabricated copings was thought to provide significant improvements in precision and this has been verified in the current study. Numerous studies have presented the Procera® technology and results for accuracy of fit are close to those presented here. Like Procera the CAMStructSURE® precision milled bar system is based on the milling of a solid titanium block and it is not surprising that results are comparable. The Cresco Ti system differs from these in that this technology is aimed at eradicating marginal discrepancies intrinsic within a cast framework and as such it is appropriate to compare data with that of the LWC group which did not benefit from this technique. Results demonstrated a highly significant difference, $p < 0.01$, for accuracy of fit and indeed the CTS technique yielded a more accurate fit than either of the milling techniques. If a cemented restoration is needed, use of laser welding of cast framework to pre-fabricated copings, should be preferred.

# Structure and mechanical properties of Cresco-Ti laser-welded joints and stress analyses using finite element models of fixed distal extension and fixed partial prosthetic designs

**Uysal, H.**
**Kurtoglu, C.**
**Gurbuz, R.**
**Tutuncu, N.**

**J Prosthet Dent**
2005;93, 235-244

**Purpose:** The Cresco Precision™ (CP) method takes advantage of laser welding technology and the knowledge that due to its material properties and its higher laser beam absorption titanium will establish a deeply penetrating weld that is as strong as the unwelded material itself. However no data exists as to the fatigue resistance of the welded joints or indeed the stresses induced within the CP frameworks, which was the purpose of this study using bench test methods and finite element calculations.

**Material and Methods:** 20 cylinders of grade 3 c.p. titanium were milled for bench analysis and testing under tension. Ten cylinders were left as unwelded controls while the other 10 were sectioned and laser welded using established conditions and welding protocols. One test specimen was sectioned and analyzed under stereo microscope to determine penetration depth and cross sectional area of welding. All remaining specimens were subjected to a uniaxial tensile test, with data on load versus percentage elongation (% strain) recorded by strain gauge. Once 0.2% proof stress was reached the samples were then loaded through to failure and both yield strength and elastic modulus calculated.

All fracture surfaces were tested for hardness and then subject to analysis under scanning electron microscope in order to classify type of fracture into one of 3 categories: 1) Fracture within spot weld 2) Fracture between weld spots 3) Fracture within parent metal with weld joint preserved. Results were subject to statistical analysis.

In addition to the above, a finite element model was designed to replicate the CP titanium cylinder supports which are welded to the framework to create a passive fit in vivo. Two prosthetic scenarios were modeled for the edentulous mandible. In model 1 (M1) a full arch beam 3.3 mm in height and 5.0 mm in bucco-lingual width was supported by 5 evenly distributed implants with 12 mm cantilevers bilaterally. In model 2 (M2) a short span beam with the same beam dimensions were used without cantilevers supported by 2 implants, one of which was angled by 30º offset to the other. Cortical and cancellous bone, as well as material properties, were assumed to be isotropic, homogenous and lineary elastic. All components and frameworks were modeled as deformable bodies in contact. The implants were modeled with an ankylotic attachment to bone to represent osseointegration and no pre-tensile stresses were assumed within the frameworks to represent a passive fit. All calculations for stress were under load conditions of 400N with 15 º linguo-axial angulations applied in M1 on the distal implants, as well as 4 mm and 10 mm along the cantilever. In M2 point of load application was first on the angled implant and then on the upright implant. Stress values were analyzed and compared to the known maximal normal stress obtained from the bench test data.

**Results:** Control specimens revealed a completely ductile type of fracture while test specimens show a combination of ductile fracture and cleavage with fracture always occurring between the weld joint and the parent metal. No porosities were observed. Comparison of data revealed that mean ultimate tensile strength (776MPa v's 574MPa) as well as yield strength, % elongation, and hardness were all significantly superior for the laser welded joints, $p < 0.001$.

The finite element calculation revealed that for both models M1 and M2 the maximum normal stresses under load were significantly lower than the ultimate tensile strength of both the welded and unwelded material. Indeed the stresses induced rarely exceeded 10% of the ultimate tensile strength. The highest stresses were recorded in the distal implants in M1 and the angulated implants in M2.

**Discussion and Conclusions:** Laser welding under previously established conditions and protocols revealed a penetration depth of 0.64mm with an absence of porosities. Furthermore the mechanical data indicated a highly significant increase in ultimate tensile strength of the welded joint which failed at the boundary with the parent metal and not within or between spot welds. This can be directly related to the optimal welding conditions of the Cresco Precision method.

In the Cresco Precision method, prefabricated titanium cylinders secured to abutment replicas are laser welded to paralleled cuts made through the chimneys above each implant at the base of the superstructure, thus incorporating perfectly fitting passive cylinders into the superstructure. In the current study it was demonstrated that when this approach was modeled, a finite element calculation predicted that maximum stresses under a load of 400N at 15º would induce a peak stress at the welded joints which did not far exceed 10% of the ultimate tensile strength of the welded titanium.

On this basis it can be deduced that given the constraints and assumptions set within the model, not least the isotropic, homogenous nature of the bone, the ankylotic nature of an osseointegrated implant and the passive fit of a Cresco prosthesis, it is unlikely that the welded joint of a Cresco-Ti framework would fail.

Further research is necessary to evaluate the fatigue life from dynamic load of these laser welded joints.



# Facilitate™

Facilitate™ is a computer guided planning tool for efficient, accurate and predictable implant treatment based on a 3D visualization of the patient's anatomy, including vital structures, implants, abutments and teeth. Facilitate is based on the successful SimPlant™ software from Materialise Dental™. The summaries present the Facilitate™ techniques and its advantages in various situations.

# A prospective study on the accuracy of mucosally supported stereolithographic surgical guides in fully edentulous maxillae

**D'haese, J.**
**Van De Velde, T.**
**Elaut, L.**
**De Bruyn, H.**

**Clin Impl Dent Rel Res**
E-pub, DOI : 10.1111/j.1708-8208.2009.00255.x

A number of studies have demonstrated a discrepancy between the planned implant positions and those achieved *in vivo.* This has been shown to be due to a number of errors that can occur within the chain of data transfer from the virtual to the real world.

**Purpose:** To report on the accuracy of the Facilitate™ software offered by Astra Tech for the placement of Astra Tech OsseoSpeed™ implants in the edentulous maxilla using mucosally-supported stereolithographic guides.

**Materials and Methods:** Thirteen patients requiring implants for the rehabilitation of their edentulous maxillae were enrolled to the study. Patients were not excluded for smoking or other typically listed contraindications. At least 3 months after the extraction of the last standing teeth, impressions were taken of their edentulous jaws for diagnostic wax-up and subsequent fabrication of a full upper denture at the correct vertical dimension. This prosthesis incorporated small radiopaque glass spheres so that it could also act as a scanning template. A dual scan procedure was undertaken and the patient and prosthesis was reconstructed in 3 dimensions using the Facilitate software. Prosthetically driven virtual planning of 6 implants was carried out on the software and all implant lengths and widths were determined accordingly. In addition the location and orientation of at least 4 fixation screws was idealized. The resulting plan was sent to the manufacturer for the fabrication of the stereolithographic surgical guide to incorporate metal sleeves for drill guidance, depth control and subsequent implant placement. Implants were generally located 3 mm submucosally to allow for the establishment of the biologic width.

Intra-operatively the guides were fixed under local anesthesia by means of the fixation screws without flap elevation and osteotomies were prepared according to the drilling menu provided by the manufacturer to ensure correct dimensions and depth control. No tissue punch was used prior to drilling. All implants were inserted through the guide to a maximum torque of 50 Ncm. After guide removal standard Uni-Abutments™ (Astra Tech) were connected and master impression taken for the conversion of the upper dentures into screw-retained fixed prostheses which were delivered within 8 hours.

Post operative CT scans were taken within 2 months and specialized software (Mimics 9.0, Materialise) was used to merge the virtual plan image with that of the actual implants *in vivo*. An iterative closet point algorithm was used to align the two images. The global, angular, depth and lateral deviation parameters were evalauated and compared for deviation between the two sets of images at both the coronal and apical ends of each implant. In addition the inter-implant distances were compared between the virtual and real post-op images. Statistical analysis was performed using SPSS software for non parametric analysis performed with the Kruskal-Wallis and Mann Whitney U tests. Differences were considered statistically significant if $p < .05$.

**Results:** One implant out of 78 placed failed to osseointegrated (1.3%) and no complications were reported with the use of the surgical guides. When comparing the virtual plan images to the actual post-operative images of the implants *in vivo* there were statistically significant deviations found for global apical position in 3 dimensions (mean apical deviation 1.13 mm), with 55% showing a deviation of > 1 mm. Although there was a coronal deviation of 0.91 mm this was not found to be statistically significant. Angular deviation varied from 0.16º to 8.86º with a mean of 2.6º. Coronal inter-implant distance varied by only 0.18 mm compared to 0.33 mm for inter-implant distance measured at the apex.

**Discussion and Conclusions:** The deviations in the current study continue to reinforce the message that one cannot wholly rely on the use of stereolithographic guides and virtual planning technology to deliver 100% accurate implant placement in 3 dimensions. However, the deviations reported in the current study are somewhat lower than has been reported previously. The small deviations in inter-implant distance suggest that deviations in apical location (in this study 0.33 mm) are the result of guide mal-position rather than intrinsic errors within the guide or through drilling errors.

It can be concluded that within the confines of existing research, the Facilitate™ software provides surgical guides which deliver acceptable accuracy compared to other published data on equivalent programs in particular when mucosally supported and secured by fixation screws. Clinicians need to be aware of the risk for angular deviations which give rise to linear apical deviations, which become accentuated for longer implants.

# Assessment of correlation between computerized tomography values of the bone and cutting torque values at implant placement: A clinical study

**Ikumi, N.**
**Tsutsumi, S.**

**Int J Oral Maxillofac Implants**
2005;20(2):253-60

**Purpose:** Initial implant stability in the bone is a prerequisite for immediate and early loading protocols. This study was performed in order to analyze if computer tomography (CT) analysis can predict a suitable implant treatment protocol. CT values were compared with the cutting torque values required for seating a self-tapping implant.

**Materials and methods:** Totally 56 implants were placed in maxillary and mandibulary bone in 13 patients. In short, a radiographic template was placed on the alveolar ridge of each patient before CT scan. Implant placement was simulated using the SimPlant Software (Materialise, Leuven, Belgium). A custom-made stereolitographic drill guide, the Surgiguide, was produced based on the same software data, to assure drilling at the planned implant positions. Implant sites were then prepared using the Surgiguide and a 3 mm diameter wide twist drill. During seating of the implants, the cutting torque values were measured using the drilling unit.

CT scan (Aquilion Multi TSX-101/4A; Toshiba) was obtained at 120 kV, 100 mA with 1.0 mm slice thickness and table increment, 1.0 second scan time and FC30 reconstruction algorithm. SimPlant imaging data was processed with ImageMaster 101. The Hounsfield units were analysed in an area defined as 1 mm from the simulated implant. At surgery a bone achored stereolitographic guide was used with stainless steel tubes as drilling guide holes (Materialise). The cutting torque value required to seat the implants into the prepared site was registered in Ncm.

Examination of correlation between CT values (Hounsfield units) and cutting torque values was performed with Pearson's correlation coefficient

**Result:** A statistically significant correlation of the CT and cutting torque values during implant placement was found ($P < 0.01$, correlation coefficient 0.77).

**Discussion and conclusion:** The classical 4 grades of defining bone quality by Lekholm and Zarb does not have the required reproducibility or objectivity. New techniques constantly evolve and information from CT scan processed in preoperative virtual planning programs are being developed. This study was performed to evaluate the relationship of CT and cutting torque values.

A strong correlation between CT and cutting torque values was found in this clinical study. The results indicate that it is possible to quantify initial implant stability and bone quality by analysis of CT. The combined CT scan and SimPlant planning makes the treatment more reliable and predictable. This is of particular importance in the maxillary molar areas where implant survival seems to be lower than at other sites, and where implant placement requires particular attention due to restricted amount and density of bone.

# Accuracy of implant placement with a stereolitographic surgical guide

**Sarment, D.P.**
**Sukovic, P.**
**Clinthorne, N.**

**Int J Oral Maxillofac Implants**
2003;18(4):571-577

**Purpose:** A novel CAD/CAM technique utilizing stereolitographic rapid prototyping have been developed in order to transfer virtual preoperative planning to the surgical field. The aim of this study was to investigate the accuracy of stereolitographic surgical guides compared to conventional surgical guides.

**Materials and methods:** One examiner planned the placement of 10 implants in each of 5 edentulous epoxy mandibles, by using SimPlant software (Materialise). Before taking CT scans of the jaws, 2 mm channels were created in the long-axis of 5 premolars (under a scanographic template) located on the right side of the jaws.

The jaw and template were scanned using a cone-beam CT scanner (Xoran Technologies) equipped with high isotropic spatial resolution. Implants were planned so that the restorative post would be in the long axis of each tooth on the right side (control). On the left side (test), where no template was present, 5 parallel implants were placed to simulate a clinical scenario. A standard surgical guide was applied on the right side and was compared to a stereolitographic Surgi-guide equipped with incremental guiding tubes on the left side.

Five experienced surgeons, independent of each other, got access to the implant planning and performed the drilling and implant placement (on one jaw each). The jaws were then returned for a comparable CT scanning. Two reference points were located; the center of the entrance of the osteotomy and center of the virtual implant apex. The location measurements were repeated twice on different days by the same examiner.

Comparisons between the test and control groups were performed using 2-tailed t-test, and standardization of measurement was established by calculating inter-examiner correlation. The inter-examiner reliability was evaluated using repeated measurements of implant lengths and angles.

**Result:** The average distance of the planned osteotomy and actual osteotomy was 1.5 mm (SD ±0.7mm) for conventional guides and 0.9 mm (SD ±0.5mm) for test guides. The distance at apex from planned to actual location was 2.1 mm (SD ±0.97mm) and 1.0 mm (SD ±0.6mm) for control and test guide respectively. These differences were statistically significant. Inter-individual variations as well as variations between surgeons were reduced using the test guide.

Statistically significant better accuracy was found at the test sites (4.5 ±2 degrees) compared to the standard technique (8 ±4.5 degrees) when analysing the angle formed between the planned and actual implant preparation.

**Discussion and conclusion:** To the authors' knowledge, this is the first attempt to compare traditional guides with CAD/CAM produced guides. The result showed on improved accuracy when using the stereolitographic CAD/CAM guide compared to the conventional guides. Variations from the mean were also reduced. However, the cost-benefit should be considered as not all patients have clear advantages of this technique. Clinical benefits are obvious when multiple parallel distant implants are placed, and for the achievement of a single prosthetic path of insertion.

# References

*Reprints can be ordered from references marked with ID No.*


Abrahamsson I, Berglundh T.
Tissue characteristics at microthreaded implants: an experimental study in dogs.
Clin Impl Dent Rel Res 2006;8(3):107-13. (ID No. 78779) ..... 14

Abrahamsson I, Berglundh T, Moon IS, Lindhe J.
Peri-implant tissues at submerged and non-submerged titanium implants.
J Clin Periodontol 1999;26(9):600-7. (ID No. 75160) ..... 31

Abrahamsson I, Berglundh T, Sekino S, Lindhe J.
Tissue reactions to abutment shift: an experimental study in dogs.
Clin Impl Dent Rel Res 2003;5(2):82-8. (ID No. 79027) ..... 30

Berglundh T, Abrahamsson I, Albouy JP, Lindhe J.
Bone healing at implants with a fluoride-modified surface: an experimental study in dogs.
Clin Oral Implants Res 2007;18(2):147-52. (ID No. 78775) ..... 6

Cecchinato D, Bengazi F, Blasi G, Botticelli D, Cardarelli I, Gualini F.
Bone level alterations at implants placed in the posterior segments of the dentition:
outcome of submerged/non-submerged healing. A 5-year multicenter, randomized, controlled clinical trial.
Clin Oral Implants Res 2008;19(4):429-31. ..... 63

Chang M, Wennström JL.
Longitudinal changes in tooth/single-implant relationship and bone topography: An 8-year retrospective analysis.
Clin Implant Dent Relat Res 2010;e-pub DOI 10.1111/j.1708-8208.2010.00272.x. ..... 62

Cooper L, Felton DA, Kugelberg CF, Ellner S, Chaffee N, Molina AL, et al.
A multicenter 12-month evaluation of single-tooth implants restored 3 weeks after 1-stage surgery.
Int J Oral Maxillofac Implants 2001;16(2):182-92. (ID No. 75410) ..... 41

Cooper LF, Ellner S, Moriarty J, Felton DA, Paquette D, Molina A, et al.
Three-year evaluation of single-tooth implants restored 3 weeks after 1-stage surgery.
Int J Oral Maxillofac Implants 2007;22(5):791-800. (ID No. 78988) ..... 33

Cooper LF, Rahman A, Moriarty J, Chaffee N, Sacco D.
Immediate mandibular rehabilitation with endosseous implants: simultaneous extraction, implant placement, and loading.
Int J Oral Maxillofac Implants 2002;17(4):517-25. (ID No. 78110) ..... 38

De Kok IJ, Chang SS, Moriarty JD, Cooper LF.
A retrospective analysis of peri-implant tissue responses at immediate load/provisionalized microthreaded implants.
Int J Oral Maxillofac Implants 2006;21(3):405-12. (ID No. 78727) ..... 39

D'Haese J, Van De Velde T, Elaut L, De Bruyn H.
A prospective study on the accuracy of mucosally supported stereolithographic surgical guides in fully edentulous maxillae.
Clin Implant Dent Relat Res E-pub Nov 10, DOI 10.1111/j.1708-8208.2009.00255.x 2009. ..... 84

Donati M, La Scala V, Billi M, Di Dino B, Torrisi P, Berglundh T.
Immediate functional loading of implants in single tooth replacement: a prospective clinical multicenter study.
Clin Oral Implants Res 2008;19:740-48. (ID No. 79065) ..... 9

Eliasson A, Blomqvist F, Wennerberg A, Johansson A.
A retrospective analysis of early and delayed loading of full-arch mandibular prostheses using
three different implant systems: clinical results with up to 5 years of loading.
Clin Impl Dent Rel Res 2009;11(2):134-48. ..... 42

Ellingsen JE.
Pre-treatment of titanium implants with fluoride improves their retention in bone.
J Mater Sci: Mater Med 1995;6:749-53. (ID No. 78327) ..... 7

Ganz SD, Desai N, Weiner S.
Marginal integrity of direct and indirect castings for implant abutments.
Int J Oral Maxillofac Implants 2006;21(4):593-9. (ID No. 79029) ..... 72

Geckili O, Bilhan H, Bilgin T.
A 24-week prospective study comparing the stability of titanium dioxide grit-blasted dental implants
with and without fluoride treatment. Int J Oral Maxillofac Implants 2009;24(4):684-88. (ID No. 79232) ..... 10

Gotfredsen K.
A 10-year prospective study of single tooth implants placed in the anterior maxilla.
Clin Impl Dent Rel Res 2009;E-pub Aug 6, DOI: 10.1111/j.1708-8208.2009.00231.x. ..... 64

Astra Tech AB is grateful to Specialist Dental Summaries Ltd for agreeing to allow the use of the layout and format of their journal Dental Implant Summaries.

Astra Tech Documentation Summaries has been written by Dr Michael Norton and the Global Scientific Management, Business Unit Dental, Astra Tech.

**Australia**
Astra Tech Pty Ltd.
Suite 1, 53 Grandview St, Pymble NSW 2073
☎ +61 2 9488 3500. 🖷 +61 2 9440 0744
www.astratechdental.com.au

**Austria**
Astra Tech GesmbH
Schloßhofer Straße 4/4/19, AT-1210 Wien
☎ +43-(0)1-2146150. 🖷 +43-(0)1-2146167
www.astratechdental.at

**Benelux**
Astra Tech Benelux B.V.
Signaalrood 55, NL-2718 SG Zoetermeer
☎ +31 79 360 1955/+32 3 232 81 50
🖷 +31 79 362 3748/ +32 3 213 30 66
www.astratechdental.nl

**Canada**
Astra Tech Inc.
2425 Matheson Blvd East, 8th Floor
Mississauga, ON L4W 5K4
☎ +1 905 361 2844
www.astratechdental.com

**Denmark**
Astra Tech A/S
Roskildevej 163, 1. th., DK-2620 Albertslund
☎ +45 43 71 33 77. 🖷 +45 43 71 78 65
www.astratechdental.dk

**East Asia**
Astra Tech
Suite 15.02, 15th Floor Menara PanGlobal
No. 8 Lorong P Ramlee, MY-50250, Kuala Lumpur
Malaysia
☎ +60 3 27 11 2531. 🖷 +60 3 27 11 2532
www.astratechdental.com

**Finland**
Astra Tech Oy
PL 96, FI-02231 Espoo
☎ +358 9 8676 1626. 🖷 +358 9 804 4128
www.astratechdental.fi

**France**
Astra Tech France
7, rue Eugène et Armand Peugeot, TSA 90002
FR-92563 Rueil Malmaison Cedex
☎ +33 1 41 39 02 40. 🖷 +33 1 41 39 02 44
www.astratechdental.fr

**Germany**
Astra Tech GmbH
An der kleinen Seite 8. DE-65604 Elz
☎ +49 6431 9869 0. 🖷 +49 6431 9869 500
www.astratechdental.de

**Italy**
Astra Tech S.p.A.
Via Cristoni, 86, IT-40033 Casalecchio di Reno (BO)
☎ +39 051 29 87 511. 🖷 +39 051 29 87 580
www.astratechdental.it

**Japan**
Astra Tech K.K.
1-7-16 Sendagaya, Shibuya-ku, Tokyo 151-0051
☎ +81 3 5775 0515. 🖷 +81 3 5775 0571
www.astratech.jp

**Norway**
Astra Tech AS
Postboks 160, NO-1471 Lørenskog
☎ +47 67 92 05 50. 🖷 +47 67 92 05 60
www.astratechdental.no

**Poland**
Astra Tech Sp.z o.o.
ul. Orężna 58, PL-02-937 Warszawa
☎ +48 22 853 67 06. 🖷 +48 22 853 67 10
www.astratechdental.pl

**Portugal**
Astra Tech
Lagoas Park, Edifício 8 – 1° piso
PT-2740-268 Porto Salvo
☎ +351 21 421 2273. 🖷 +351 21 421 0234
www.astratechdental.pt

**Spain**
Astra Tech S.A.
Calle Ciencias nº 73 derecha. Nave 9,
Polígono Industrial Pedrosa,
ES-08908 L'Hospitalet de Llobregat
☎ Servicio al cliente: +34.902.101.558
☎ +34.932.643.560. 🖷 +34.933.363.231
www.astratechdental.es

**Sweden**
Astra Tech AB
P.O. Box 14, SE-431 21 Mölndal
☎ +46 31 776 30 00. 🖷 +46 31 776 30 17
www.astratechdental.se

**Switzerland**
Astra Tech SA
Avenue de Sévelin 18, P.O. Box 54
CH-1000 Lausanne 20
☎ +41 21 620 02 30. 🖷 +41 21 620 02 31
www.astratechdental.ch

**United Kingdom**
Astra Tech Ltd.
Brunel Way, Stonehouse, Glos GL10 3SX
☎ +44 845 450 0586. 🖷 +44 1453 791001
www.astratechdental.co.uk

**USA**
Astra Tech Inc.
590 Lincoln Street, Waltham, MA 02451
☎ +1-800-531-3481. 🖷 +1-781-890-6808
www.astratechdental.com

**Other Markets**
Astra Tech AB, Export Department
P.O. Box 14, SE-431 21 Mölndal, Sweden
☎ +46 31 776 30 00. 🖷 +46 31 776 30 23
www.astratechdental.com

Printed in Sweden by Typografia

# Checklist for critical reading of clinical documentation and scientific articles

Reading scientific articles and clinical documentation is essentially about being able to judge how reliable the results are and what they mean for you in your clinical work. In order for a scientific article to be deemed credible, certain data must be present. Here is a list of important and necessary information to look for:

## ☐ Purpose of the study

Why was the study performed? The purpose should be compared with the conclusion.

## ☐ Type of study

Is it a prospective or retrospective study? Generally, prospective studies are better, since the criteria are set before the patients are treated.

## ☐ Number of clinics involved

How many clinics are involved? More than one clinic should be involved in the study, in order to judge the possibility of repeated results.

## ☐ Number of patients

How many patients are included in the study?

## ☐ Inclusion and exclusion criteria

What are the criteria for a patient to be included in or excluded from the study?

## ☐ Number of implants for upper and lower jaws respectively

The number of implants should always be listed separately for upper and lower jaws, including failure statistics, as the treatment prognosis is different in each jaw. An additional advantage is if you can see the difference between anterior and posterior treatment.

## ☐ Follow-up

How many implants have been followed for how long? When did the follow-up start; at installation or at loading?

## ☐ Indications

Which indications are covered in the study; single, partial or full bridge? If it is a full bridge, is it fixed prosthesis or overdenture?

## ☐ Loading

When were the implants loaded (immediate, early or conventional loading)?

## ☐ Implants lost

A study should include both the number of implants and number of patients not accounted for during the entire follow-up period. It should also include the reasons for drop-outs.

## ☐ Success criteria

What is a successful result according to the authors? It is important that the success criteria are clearly described.

## ☐ Other important parameters

How were the results verified? Was x-ray used when determining bone levels? How were bone levels measured? Was the bridge removed to control implant stability?

## ☐ Statistical analysis of success and failure rates

A study should include statistical facts and figures to reveal how many implants were actually followed up and for how long. It should also include a "worst-case" analysis, meaning a calculated failure rate assuming that all drop-outs were lost implants.

## ☐ Complications

If there are complications or drop-outs, they should be clearly described.

## ☐ Conclusion

The conclusion should be compared with the purpose of the study. Was it fulfilled? What does the study actually tell you? How does the result affect your daily clinical work?

ASTRA ASTRA TECH

A company in the AstraZeneca Group

Astra Tech AB, Aminogatan 1, P.O. Box 14, SE-431 21 Mölndal, Sweden. ☎ +46 31 776 30 00. 🖷 +46 31 776 30 10.
www.astratechdental.com